

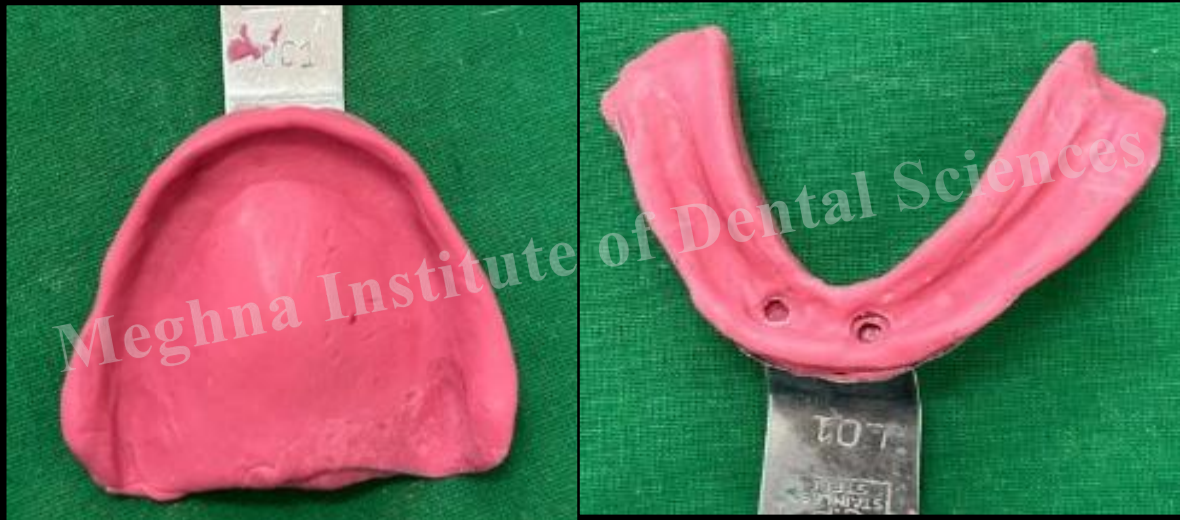Rehabilitation Of Completely Edentulous Patient With Implant Supported Overdenture In Mandible For Better Retention

A 60 yrs old female patient named Narsamma came to the Department of prosthodontics with the chief complaint loose dentures. On examination resorbed mandibular ridge were noticed & two implants were placed and given the implant supported overdenture.

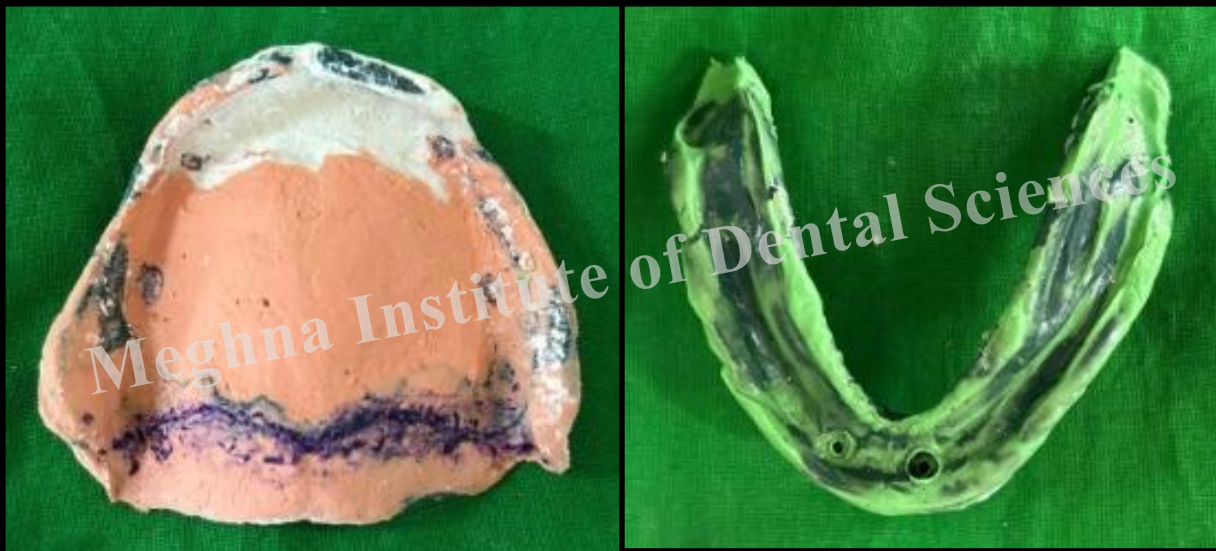PRE-OP & POST-OP VIEW



STEPS IN FABRICATION



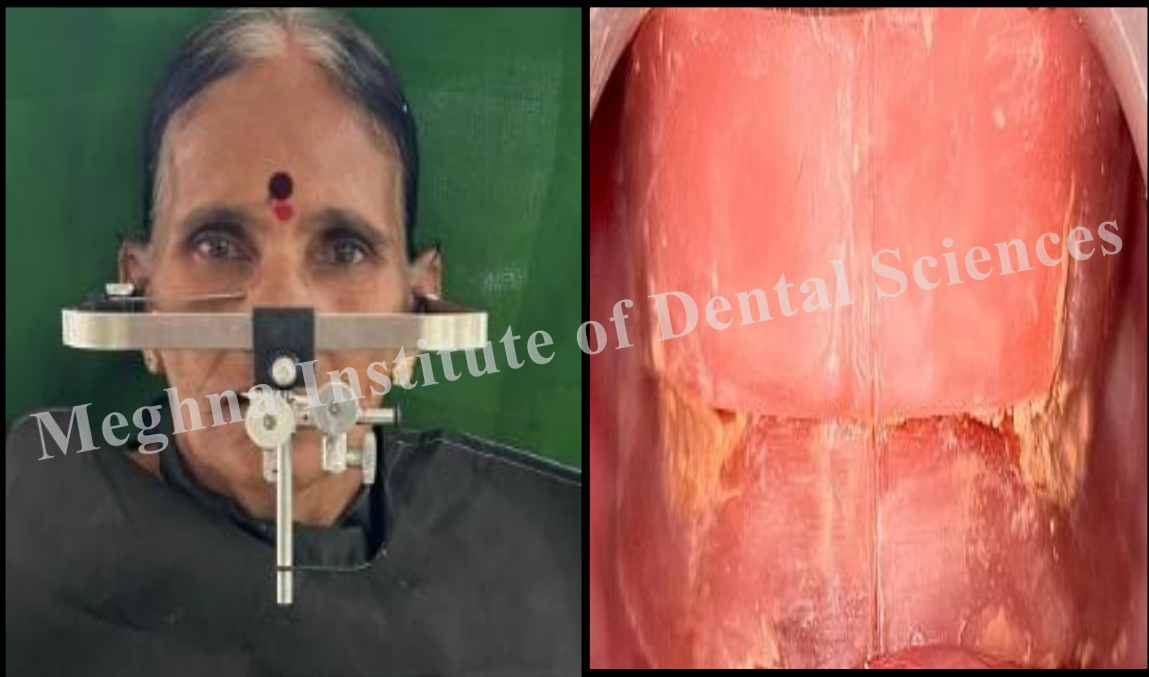
Primary Impressions



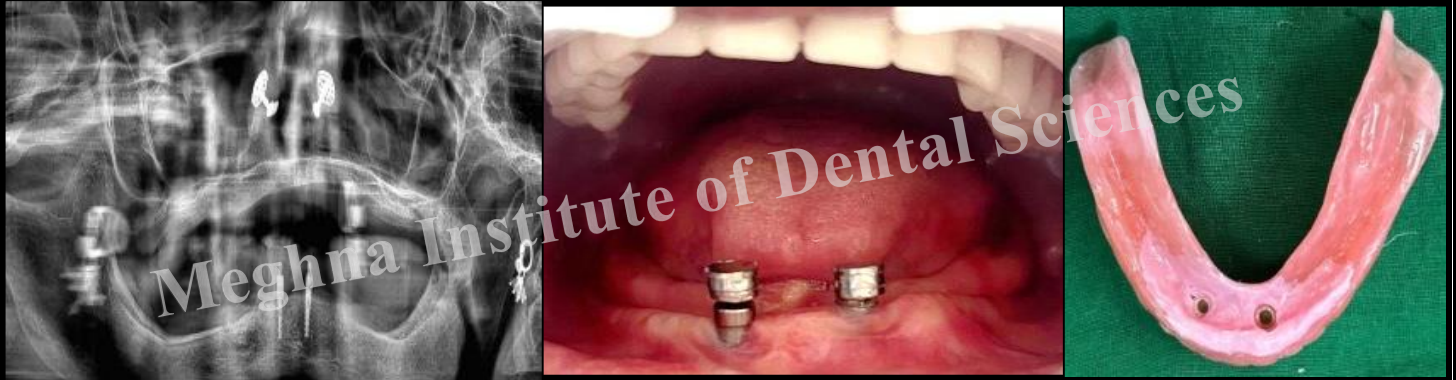Border Moulding & Secondary Impression



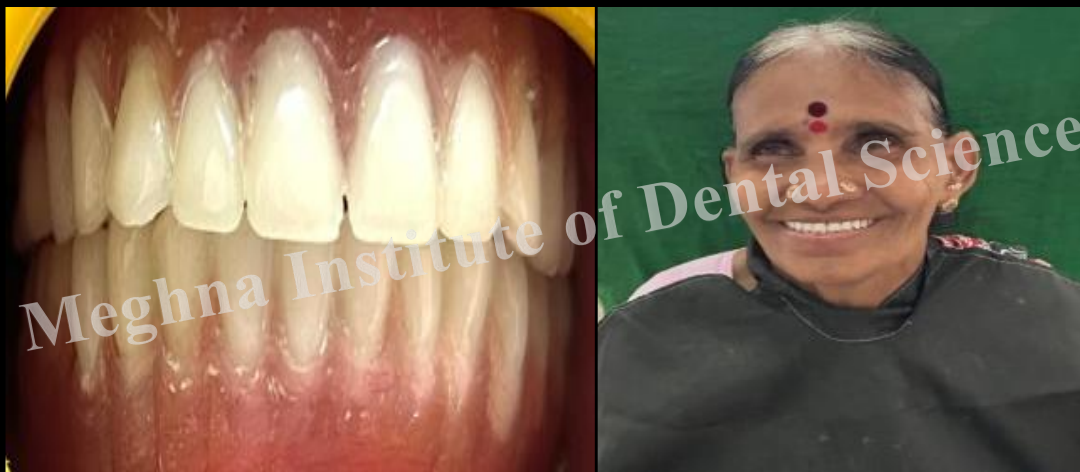Final Cast



Face Bow Transfer & Jaw Relations



Precisions Attached To Ball Attachments



Denture Try-In

HAPPY PATIENT

Implant supported over denture is used in patients with difficulty in retaining conventional dentures for increasing retention, stability and better chewing efficiency