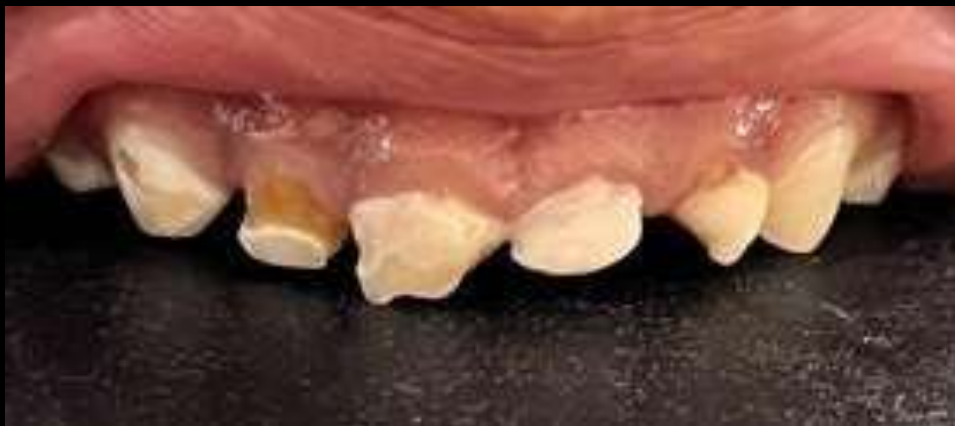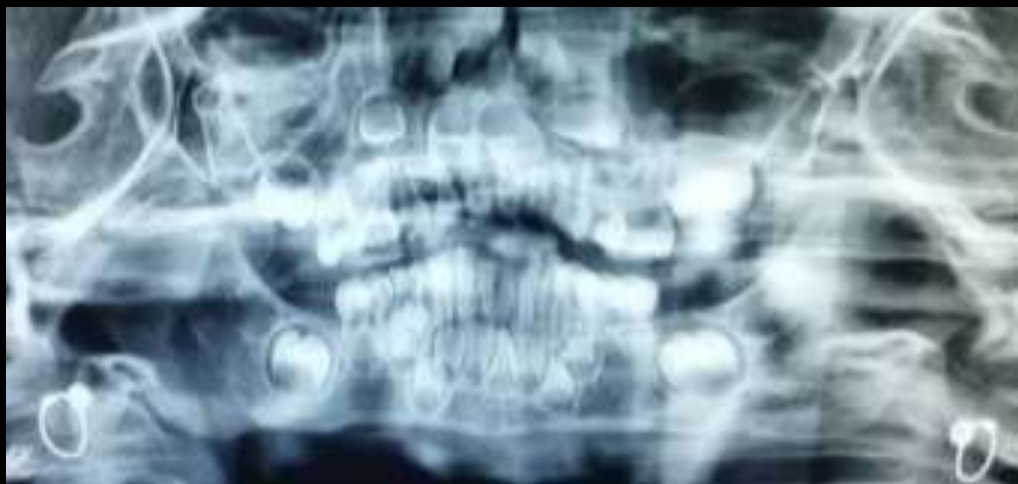


A CASE OF ESTHETIC REHABILITATION

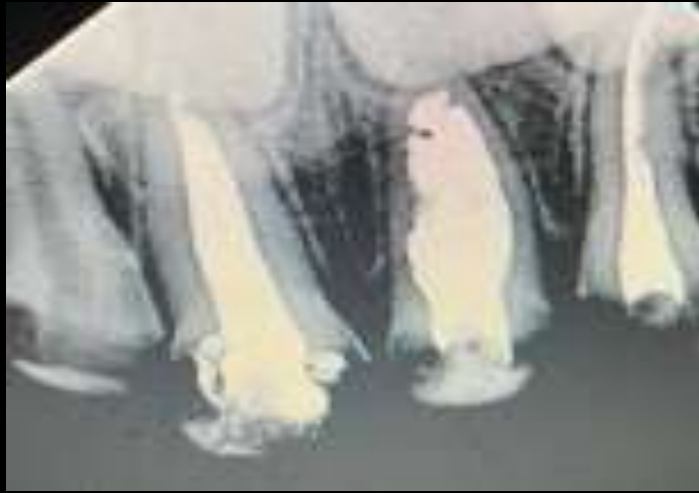A 4 years old girl patient named Hanvika reported to the department of pediatric and preventive dentistry with the chief complaint of blackish discoloration in the front tooth region in the last 6 months. Based on the clinical and radiographic examination a final diagnosis of early childhood caries is given treatment plan which was done was pulpectomy done irt 51,61,62 followed by tooth preparation followed by edelweiss crowns and vital tooth preparation done irt 52 followed by tooth preparation followed by edelweiss crowns



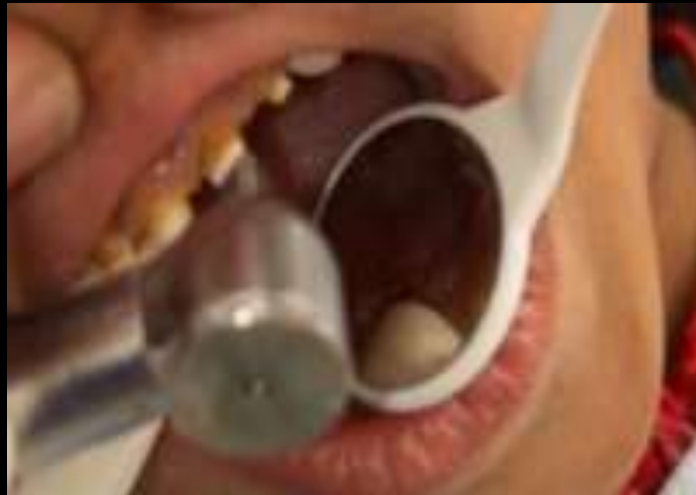PRE OP FRONTAL VIEW



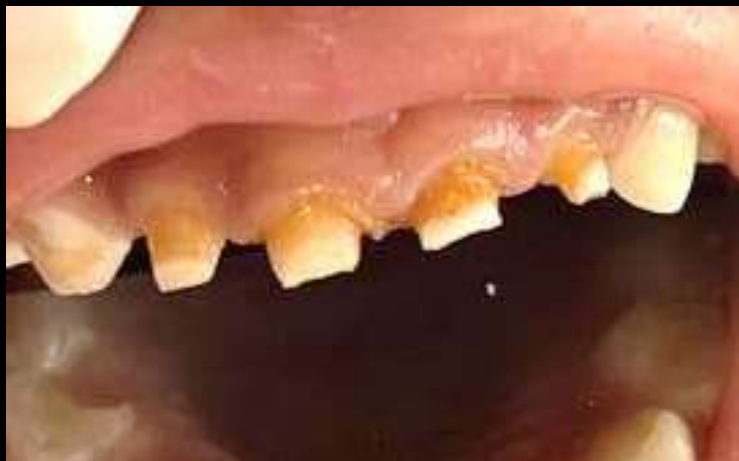PRE OP RADIOGRAPH



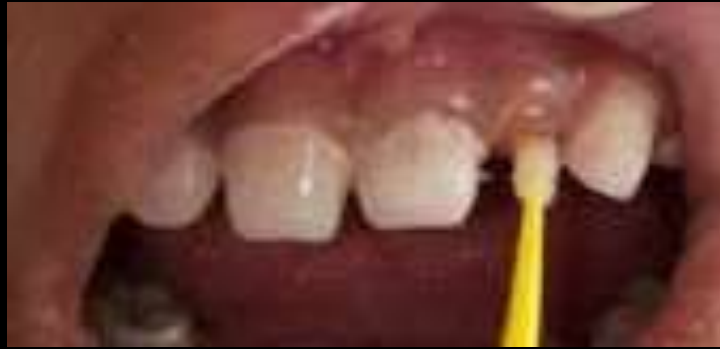**PULPECTOMY DONE
IRT 51,61,62**



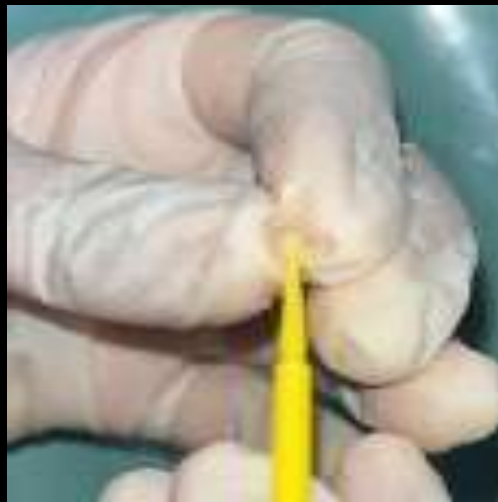**TOOTH PREPARATION IRT
51,52,61,62**



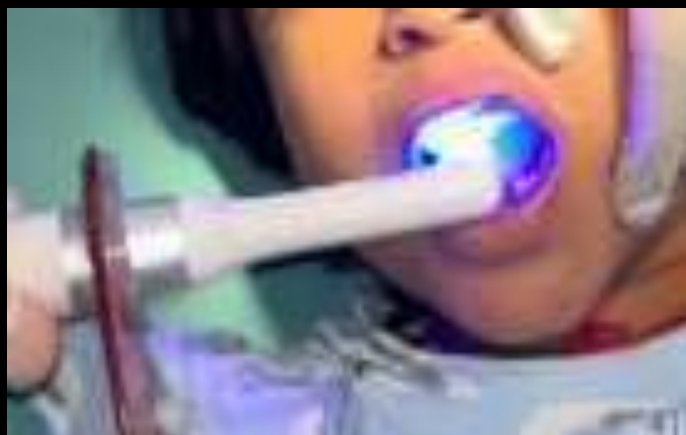TOOTH PREPARATION DONE



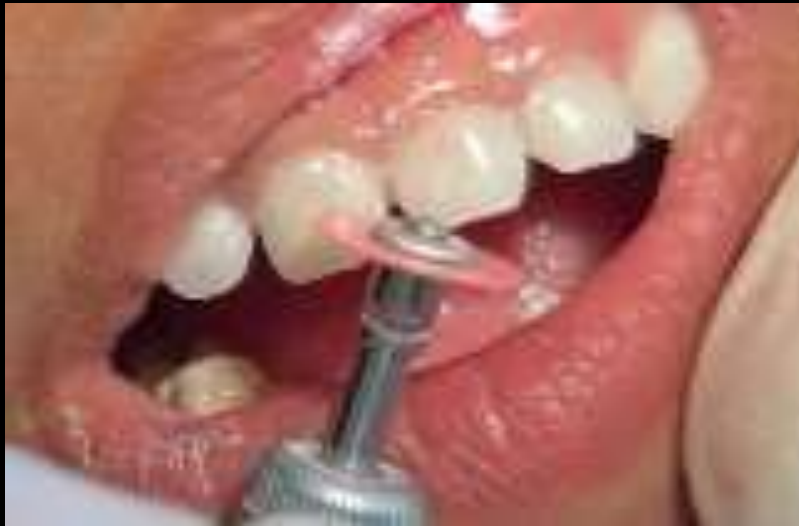**ETCHING AND BONDING
TOOTH SURFACE**



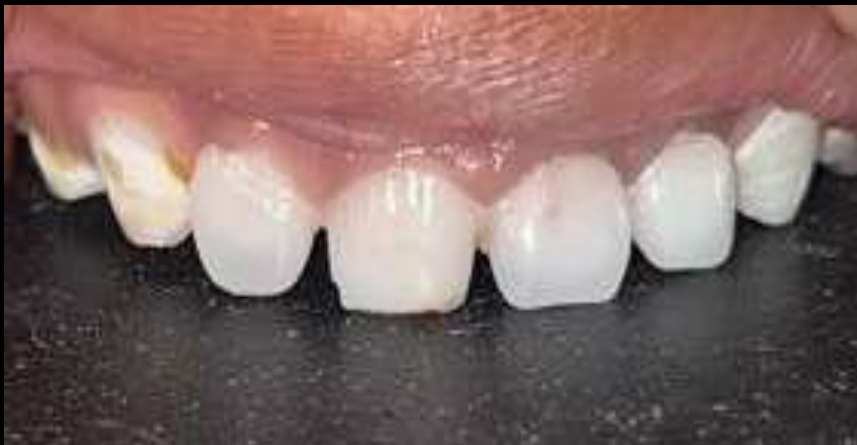**BONDING THE CROWN
WITH VENEER BOND**



**CURING AFTER CROWN
PLACEMENT**



**POLISHING THE CROWNS
AFTER PLACEMENT**



**POST-OP FRONTAL VIEW
AFTER PLACING
EDELWEISS CROWNS IRT
51,52,61,62**