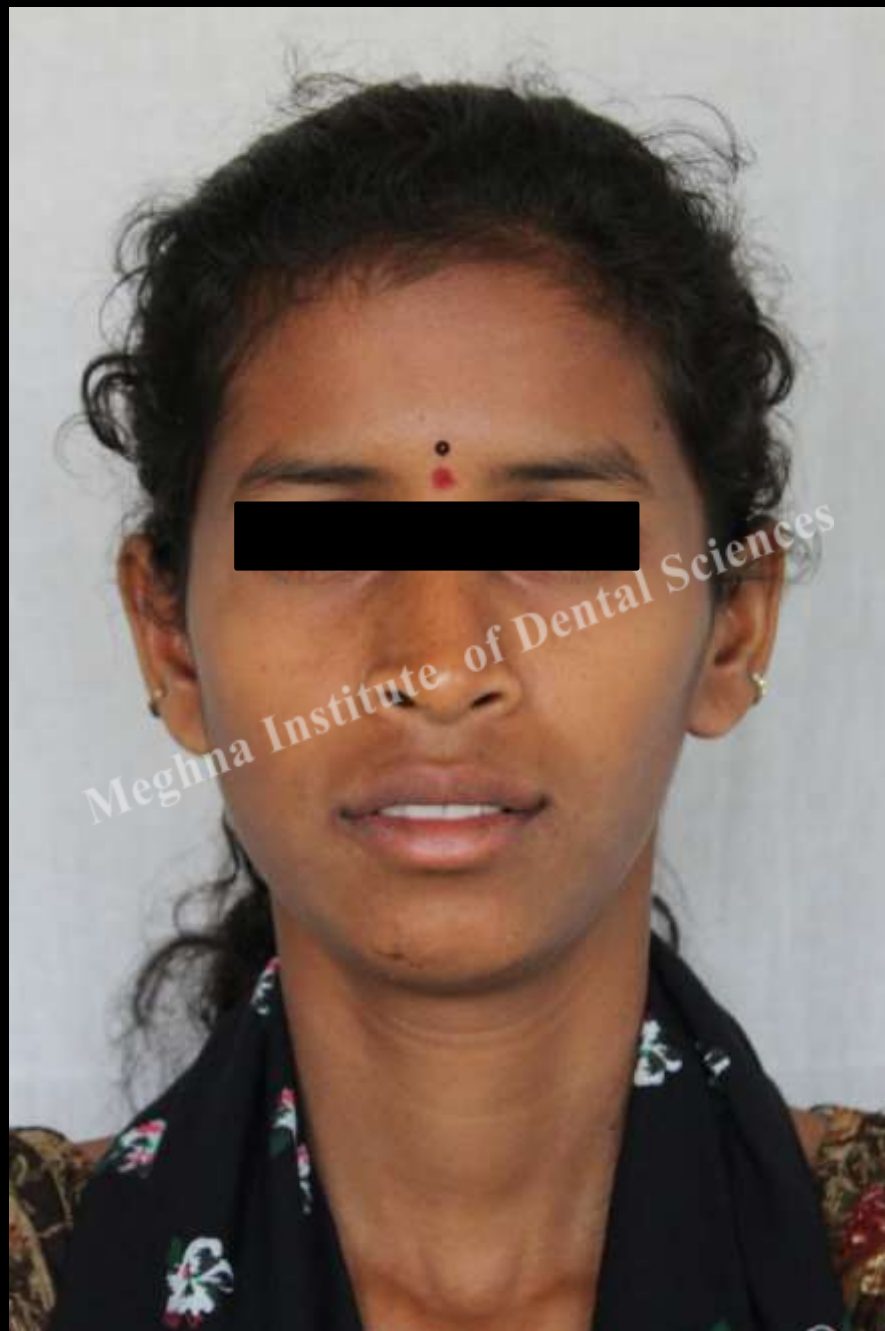
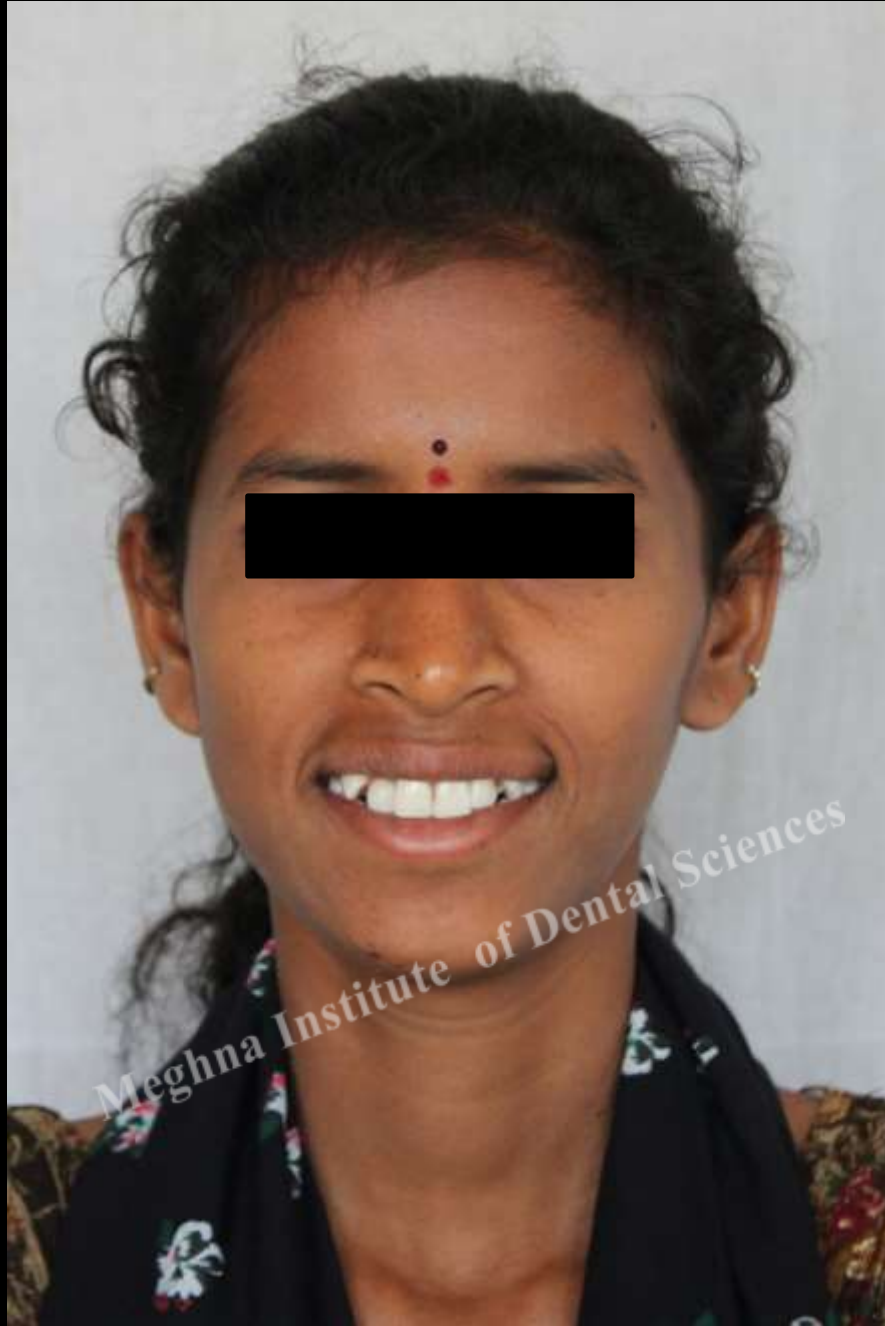
## Individual canine retraction with T loop

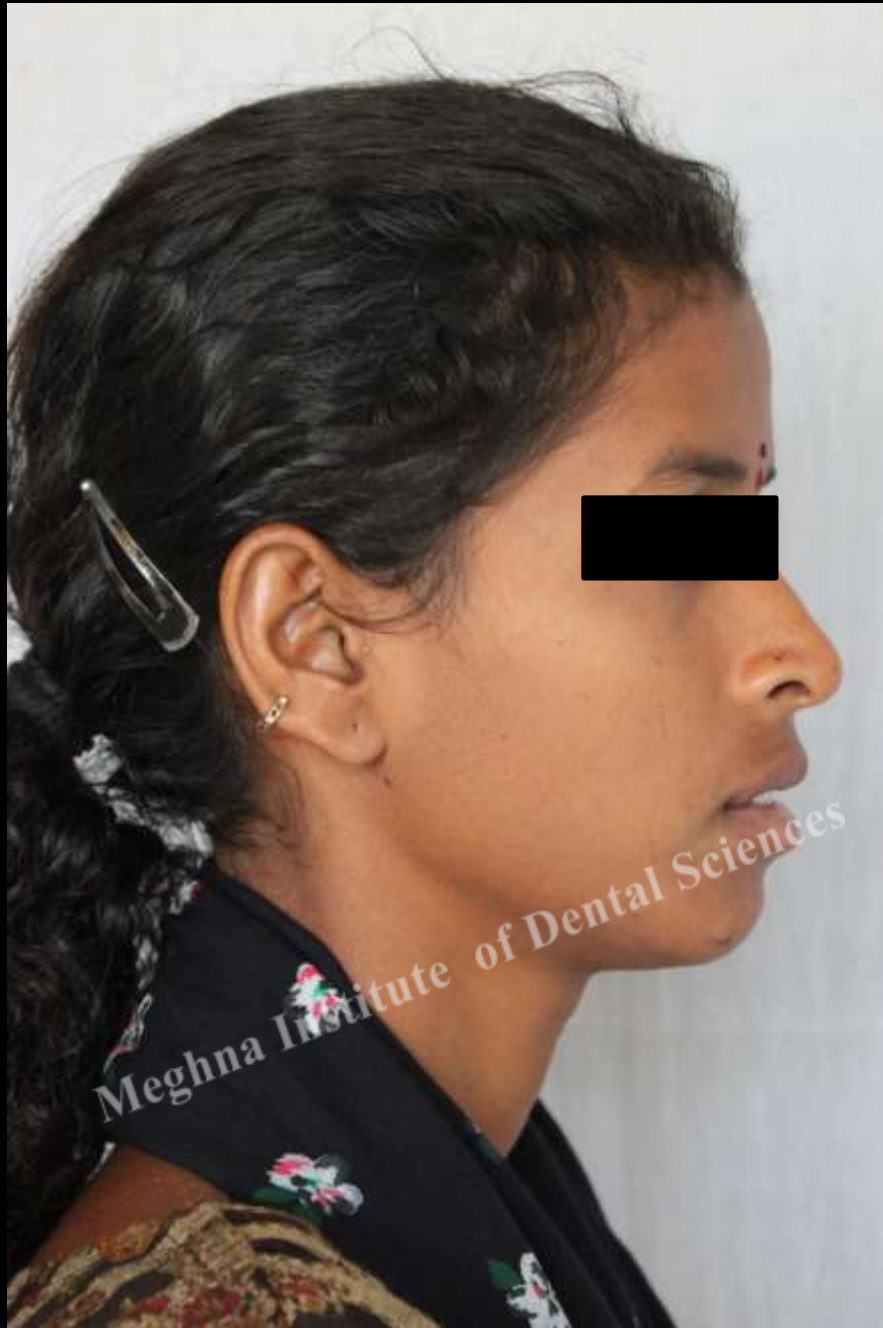A 18year old adult female patient with chief complaint of irregularly placed upper front teeth, with no relevant medical history. Treatment was planned to extract the upper first premolars to relieve crowding and lower second premolars to mesialize the molars and achieve class I malocclusion.



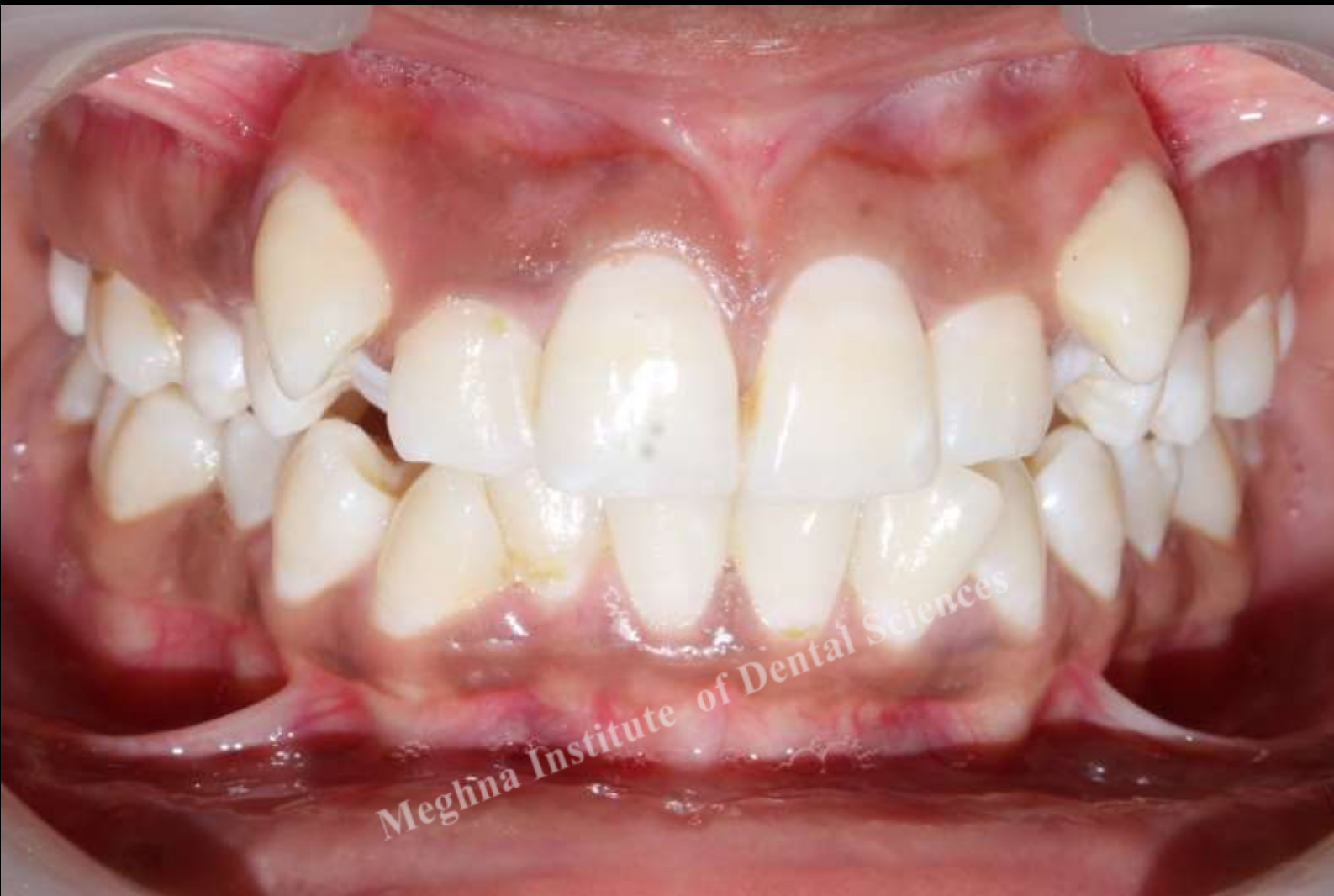Pre treatment frontal photograph



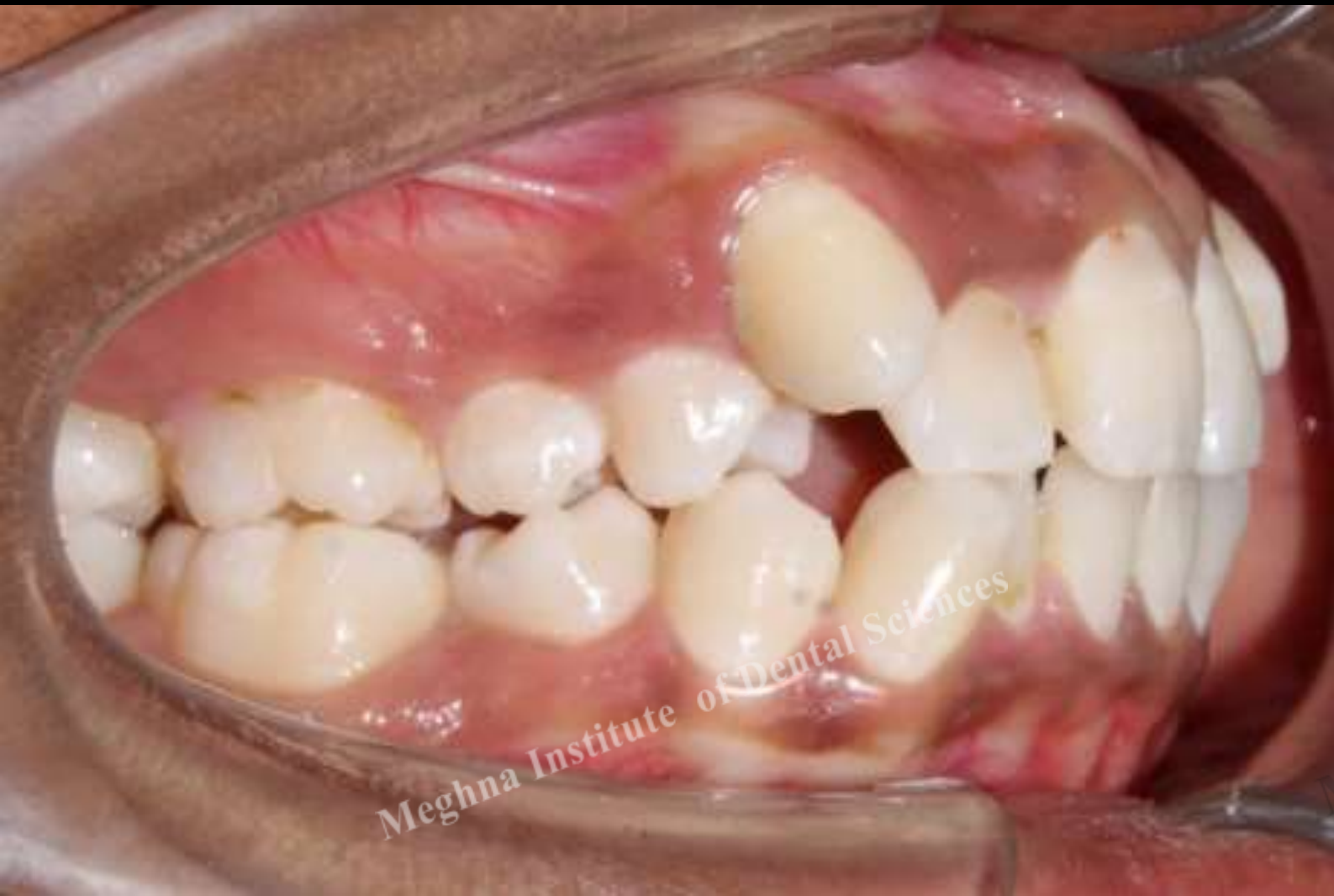Pre treatment smiling photograph



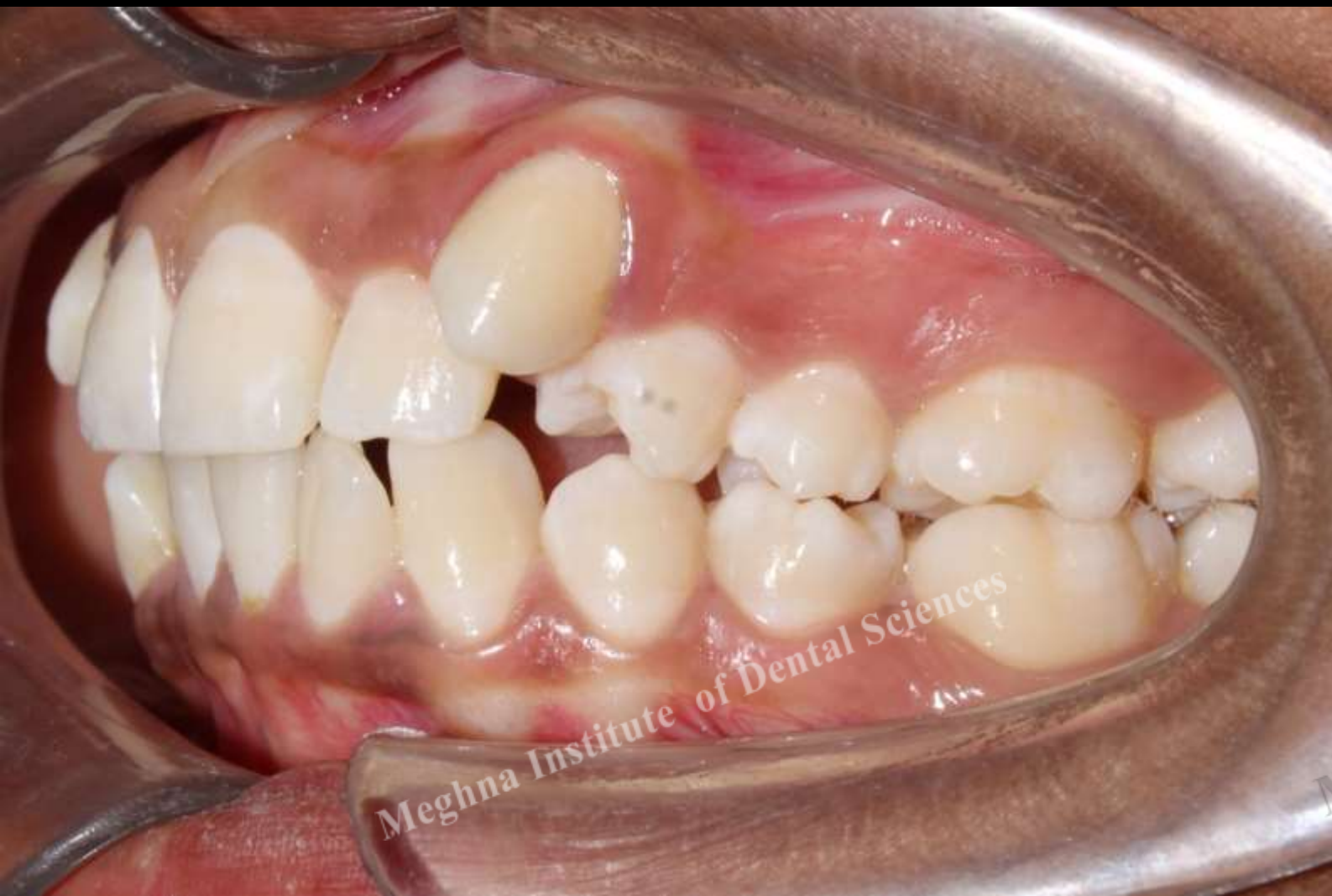Pre treatment profile photograph



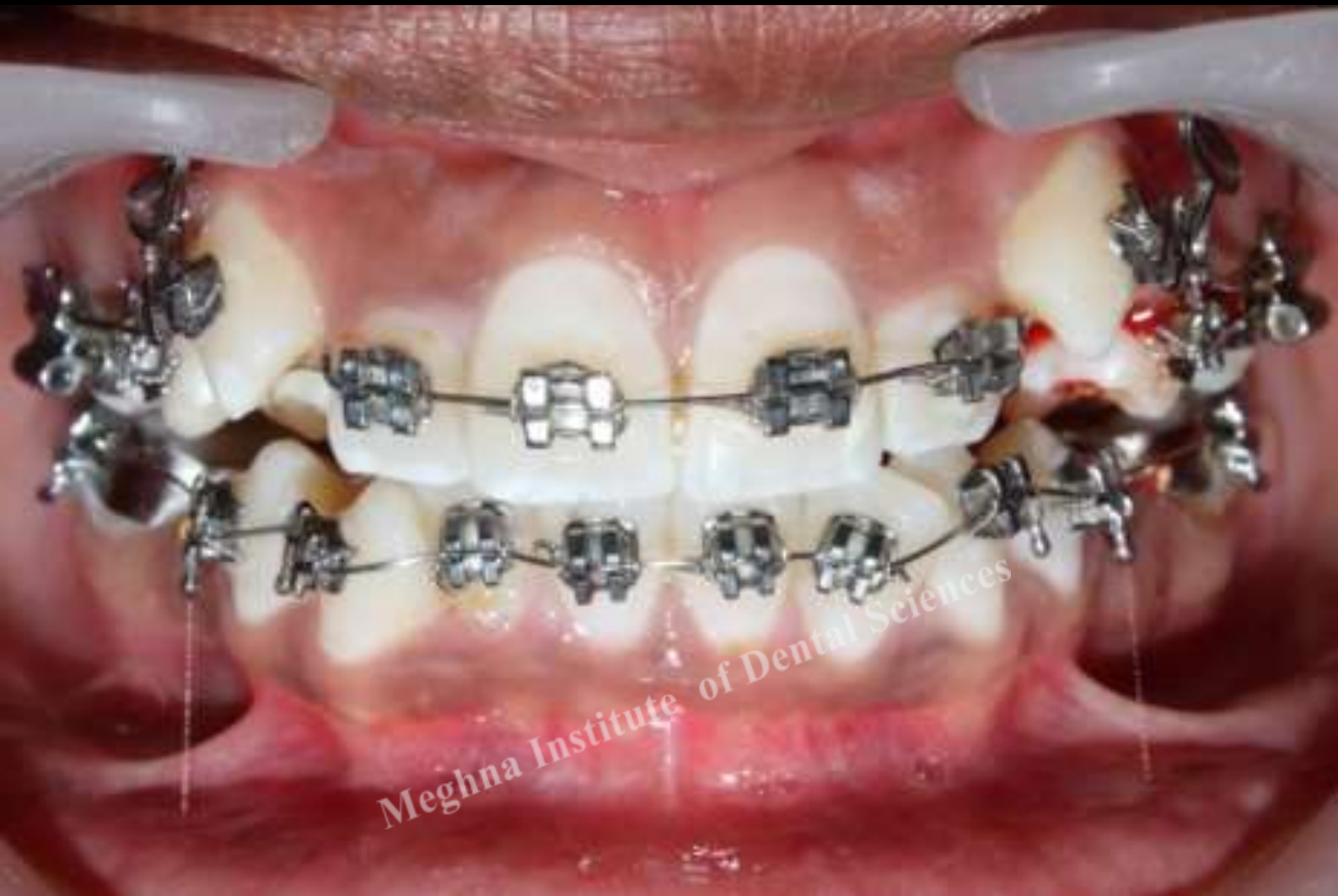Pre treatment intraoral frontal photograph



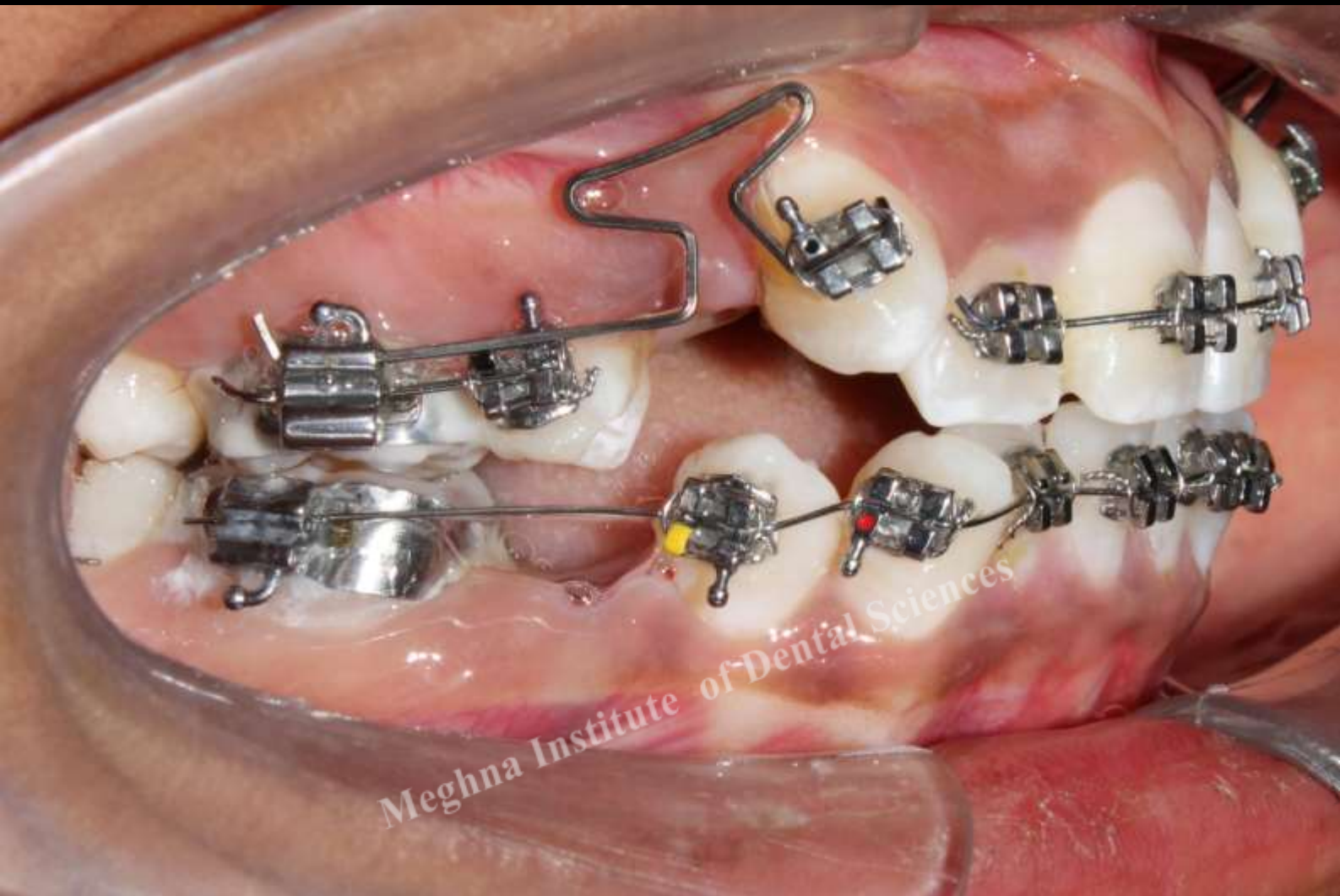
Pre treatment intraoral right buccal photograph



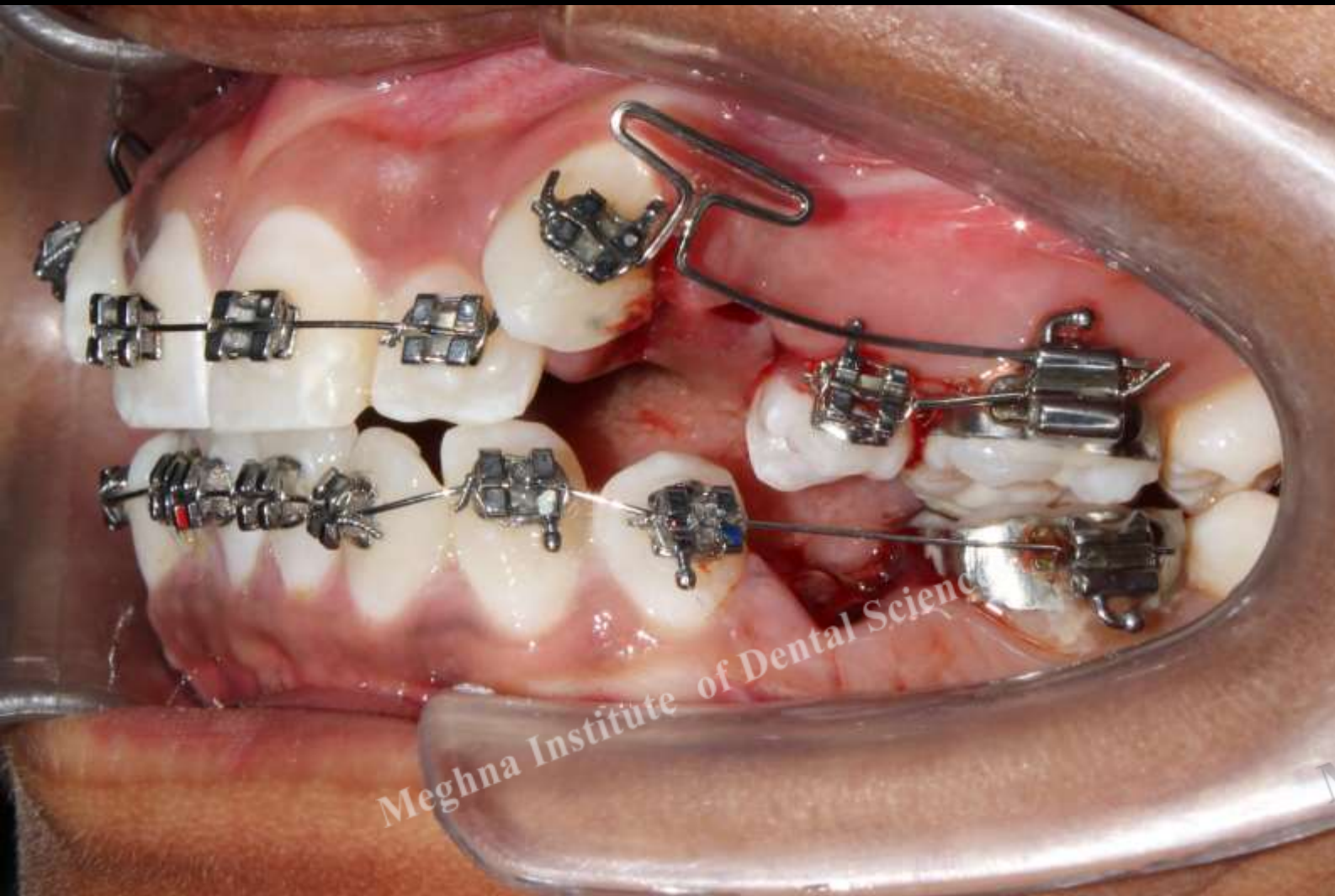Pre treatment intraoral left buccal photograph



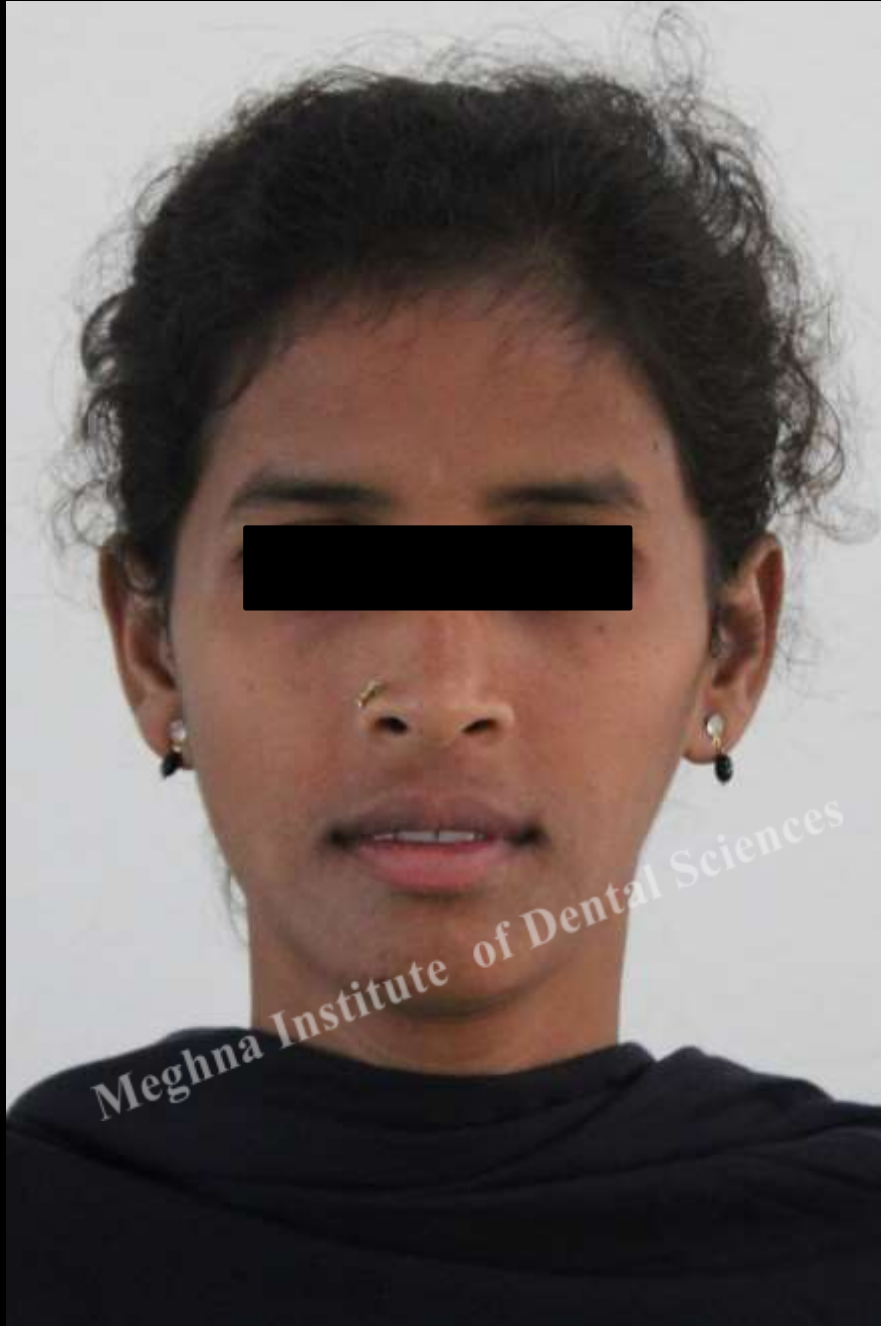Individual canine retraction with T loop  
intraoral frontal photograph



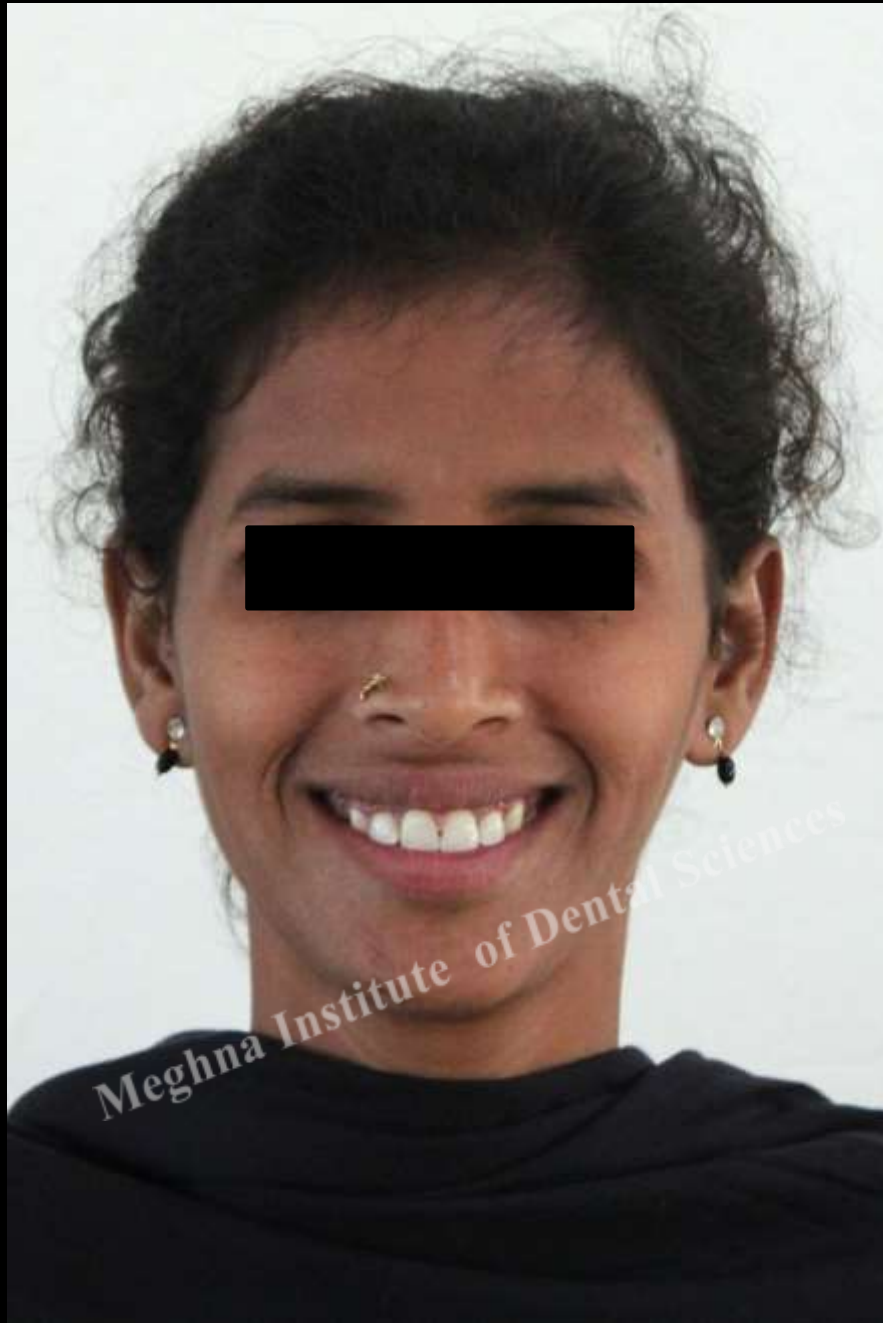Individual canine retraction with T loop  
intraoral right buccal photograph



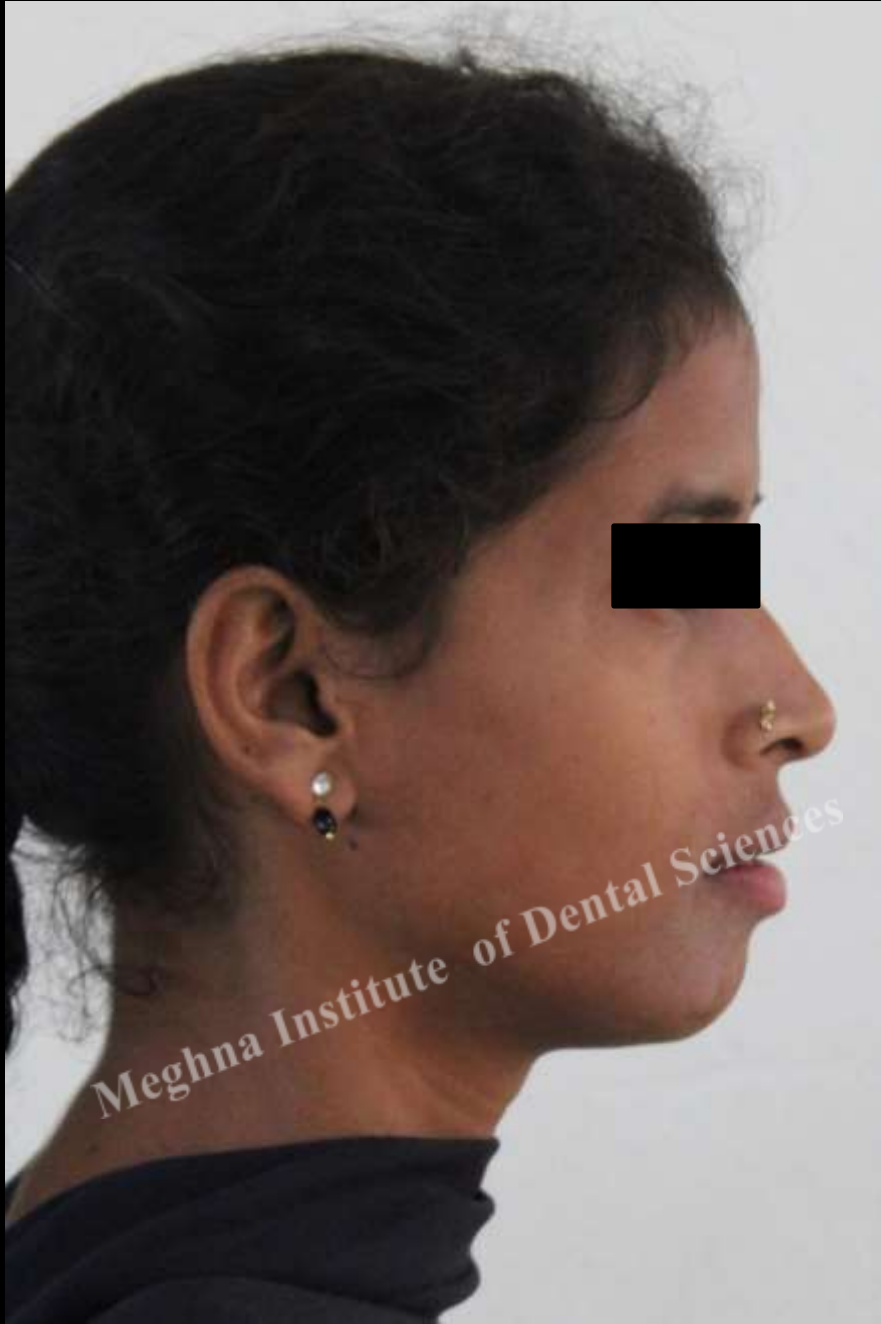Individual canine retraction with T loop  
intraoral left buccal photograph



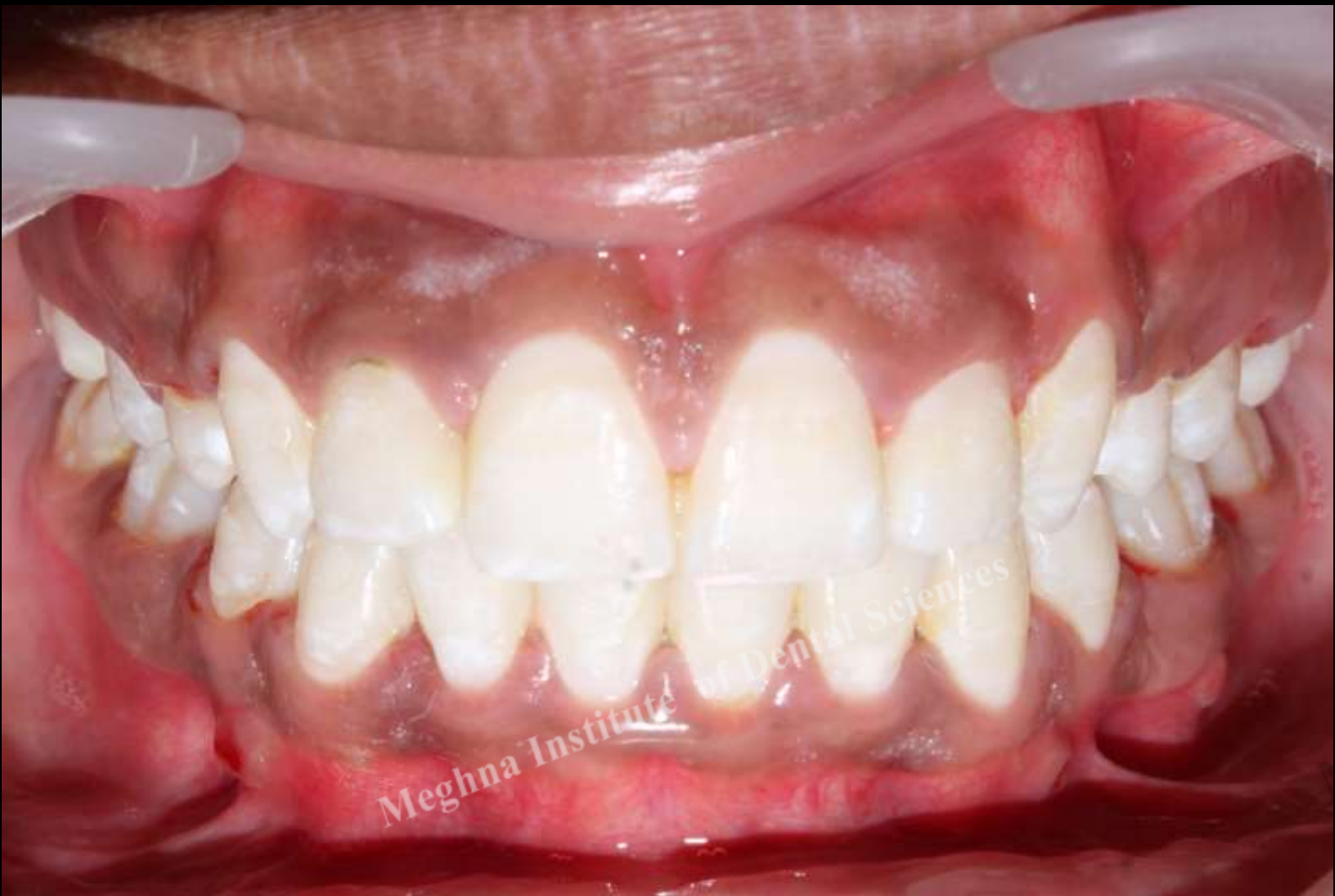Post treatment frontal rest photograph



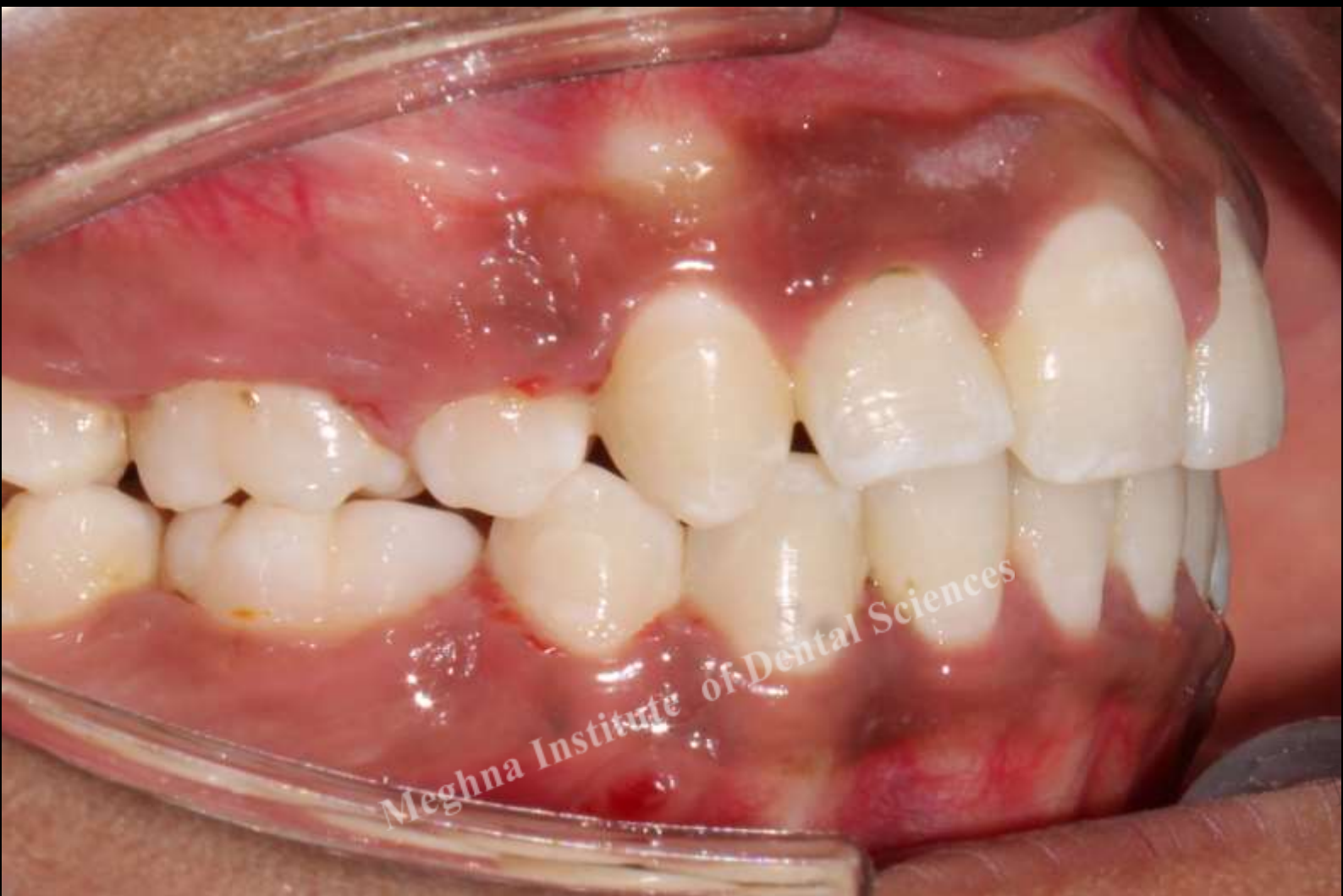Post treatment frontal smiling photograph



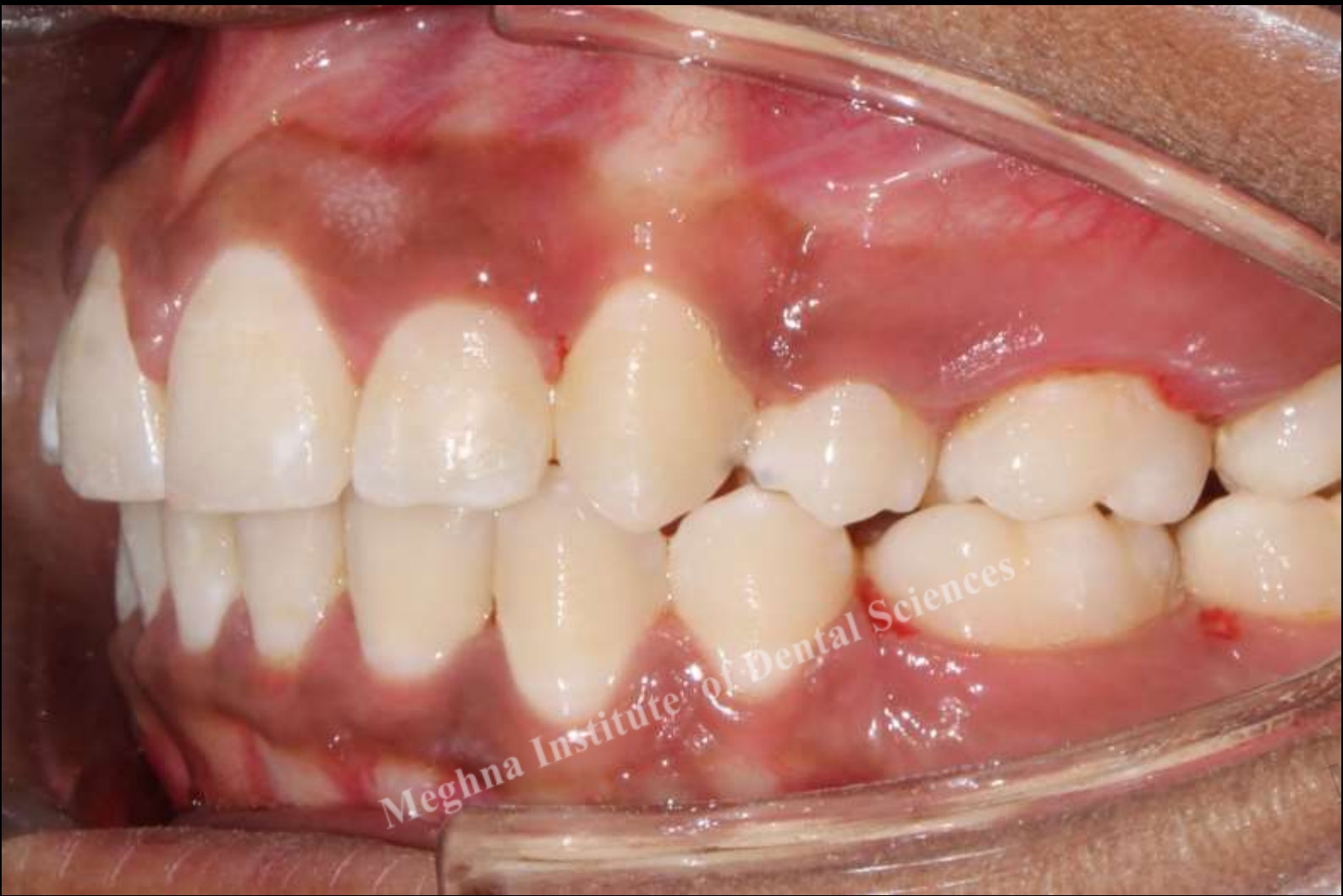Post treatment profile photograph



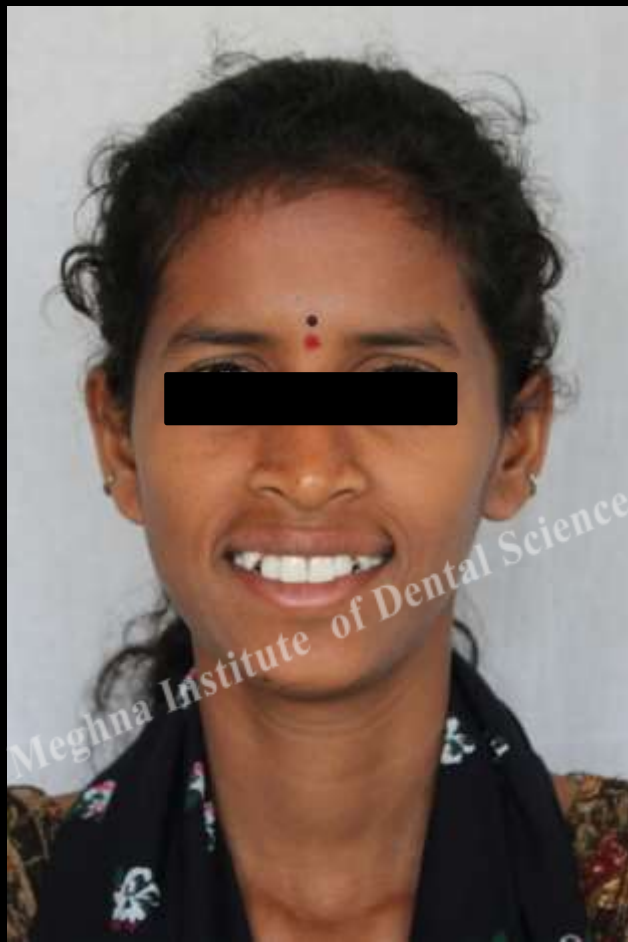Post treatment intraoral frontal photograph



Post treatment intraoral right buccal photograph



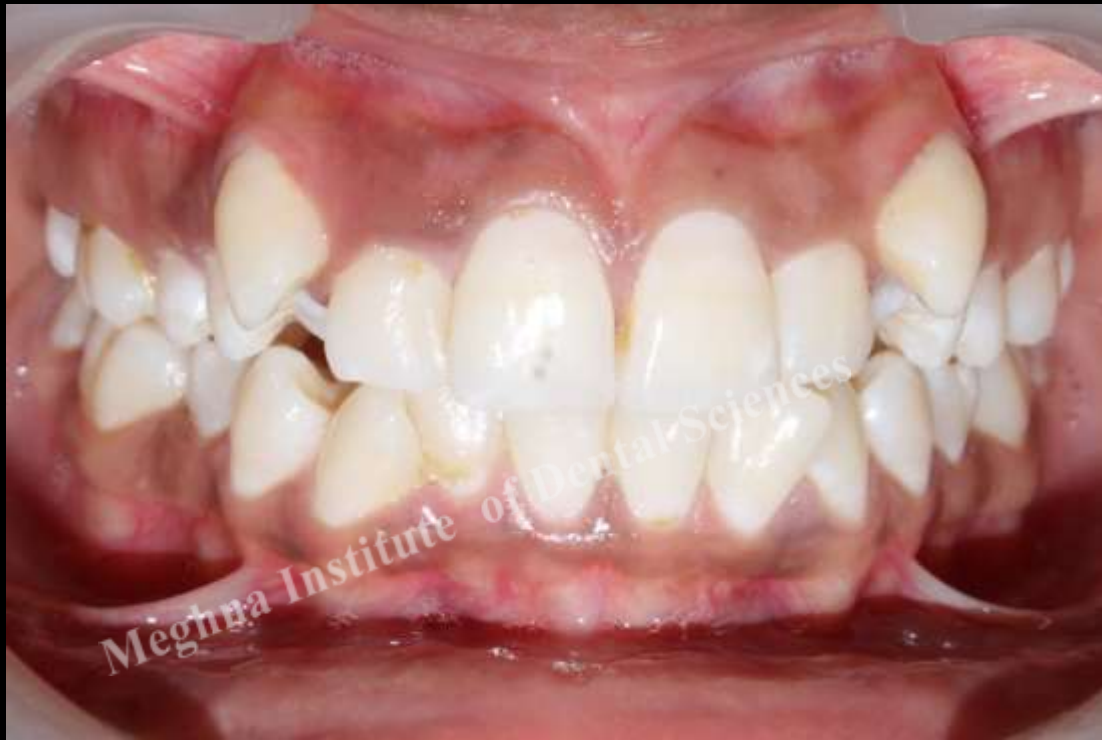Post treatment intraoral left buccal photograph



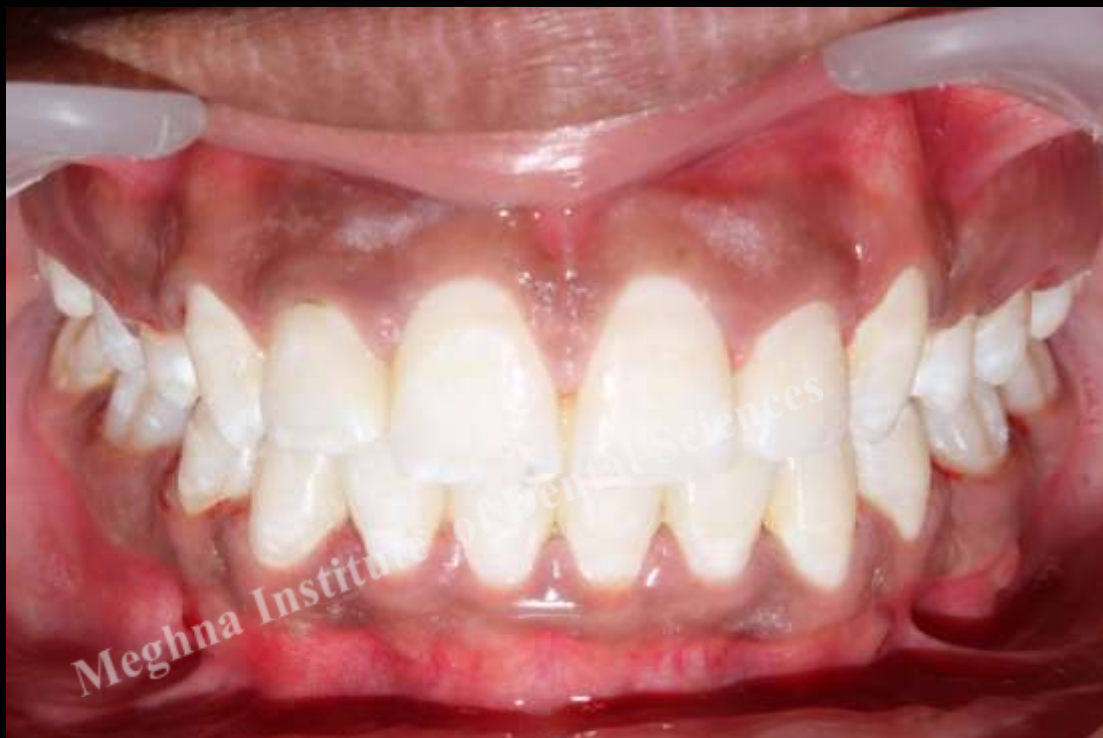Pre treatment frontal smile photograph



Post treatment frontal smile photograph



Pre treatment introral frontal photograph



Post treatment intraoral frontal photograph