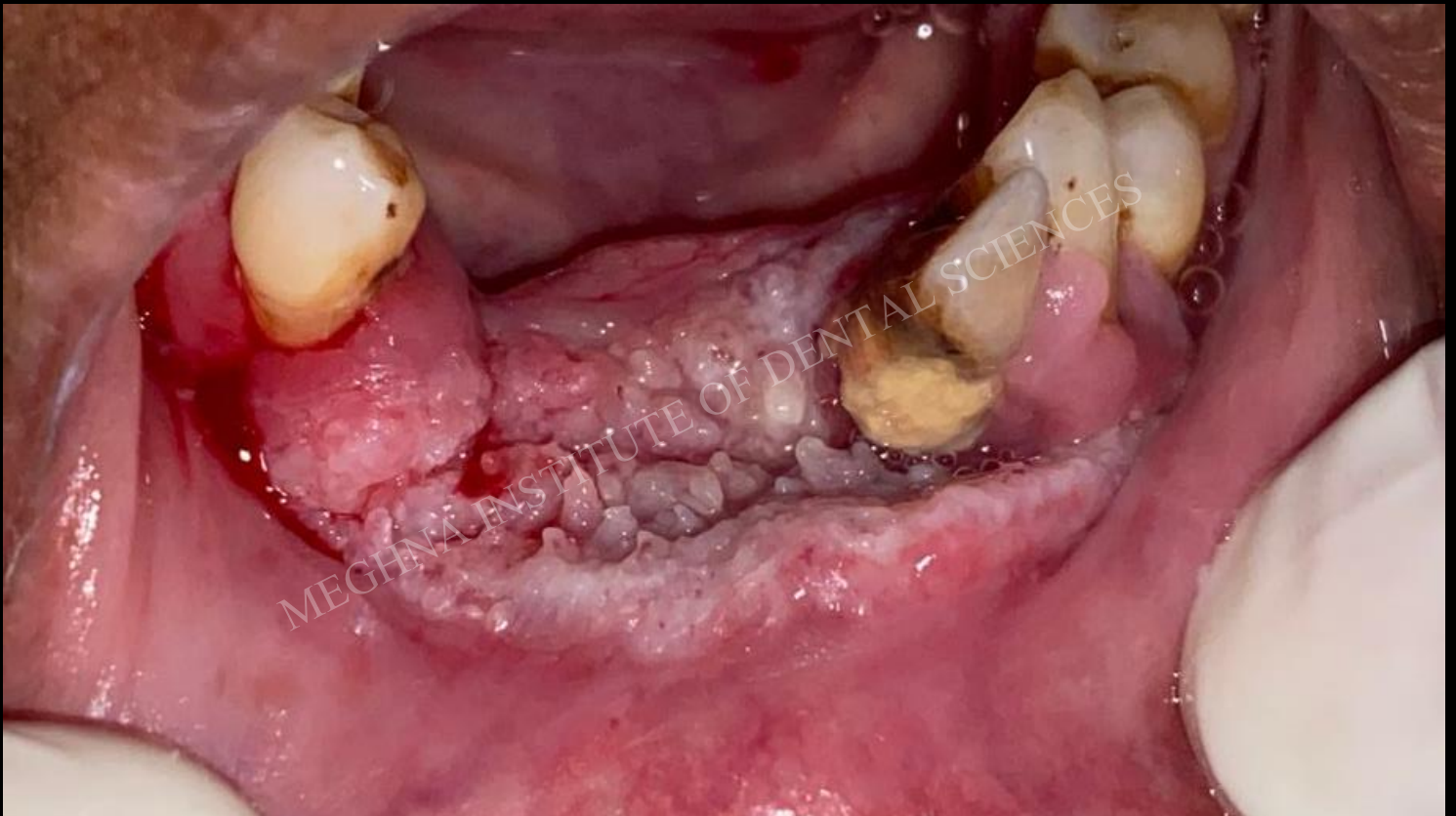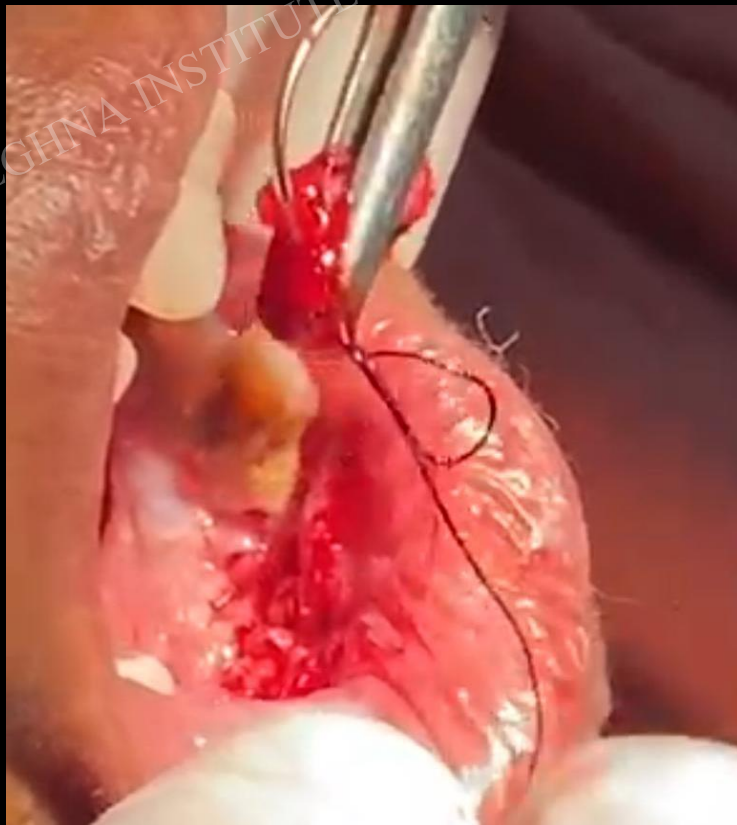
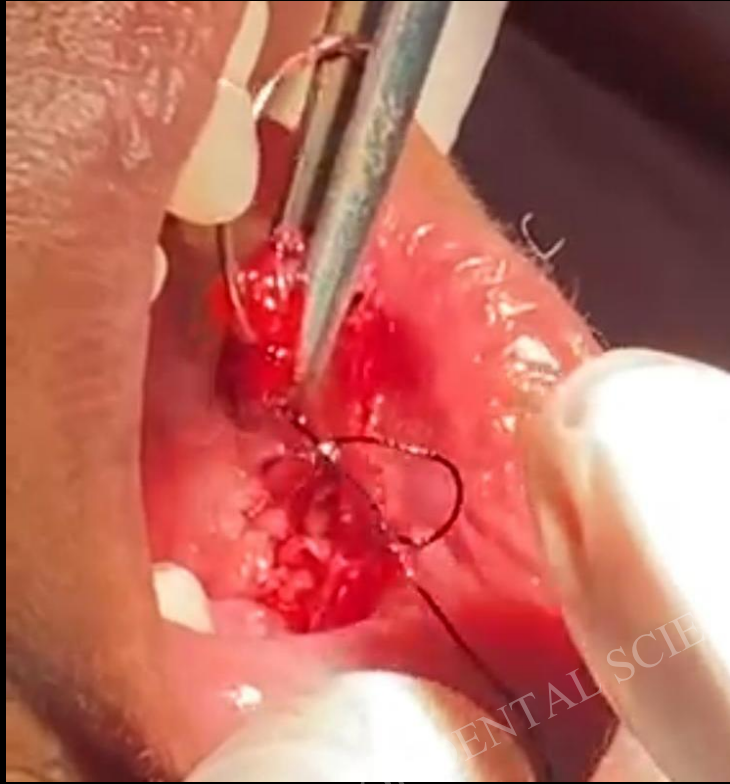


A Case of An Oral Malignancy

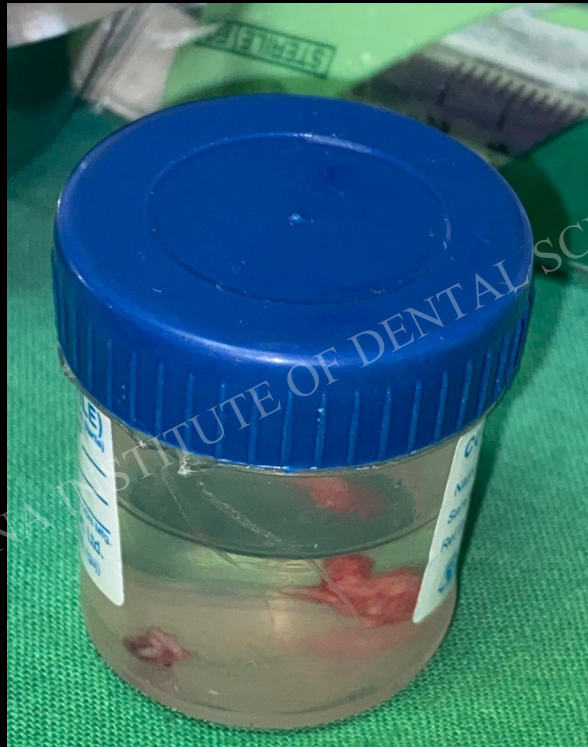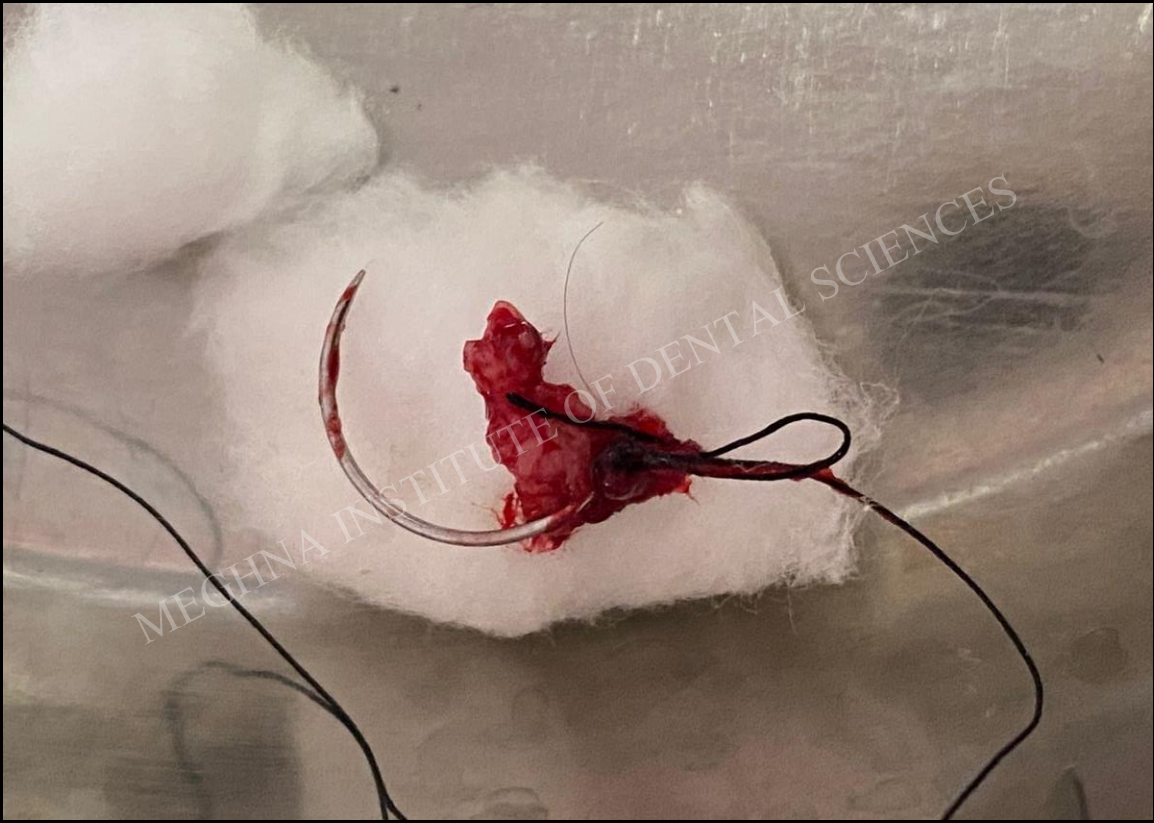
A 50-year-old female patient named Chinnu bai reported to the Department of Oral Medicine and Radiology, with a chief complaint of pain in the lower front tooth region since, 2 months. The patient gave a history of tobacco chewing for 5 years. On intraoral examination, a solitary ulcerated lesion was seen involving the lower labial vestibule and alveolar mucosa. The lesion exhibited a cauliflower-like surface texture, appeared whitish-pink with focal erythematous areas, and showed bleeding on provocation with no palpable lymph nodes. Based on the clinical findings, a provisional diagnosis was given as ulcero-proliferative growth involving anterior mandible. Incisional biopsy was performed after routine hematological investigations, which were within physiological ranges. The specimen was sent for histopathological examination, where the report ruled out as the lesion is conclusive of being Squamous cell carcinoma.



PRE-OPERATIVE



INCISIONAL BIOPSY WAS DONE



EXCISED TISSUE WAS SENT FOR HISTOPATHOLOGICAL EXAMINATION, WHICH WAS RULED OUT AS "SQUAMOUS CELL CARCINOMA"