SMILE DESIGNING

A 23 year old male patient reported to DEPARTMENT OF ORAL AND MAXILLOFACIAL PROSTHODONTICS AND IMPLANTOLOGY for replacement of anterior missing tooth.

On examination one anterior tooth was not present but, there was more available edentulous space because of diastema ,with proper smile designing his esthetics were established and regained his confidence back .







FRONTAL VIEW



MAXILLARY OCCLUSAL VIEW



MANDIBULAR OCCLUSAL VIEW



LEFT LATERAL VIEW



RIGHT LATERAL VIEW

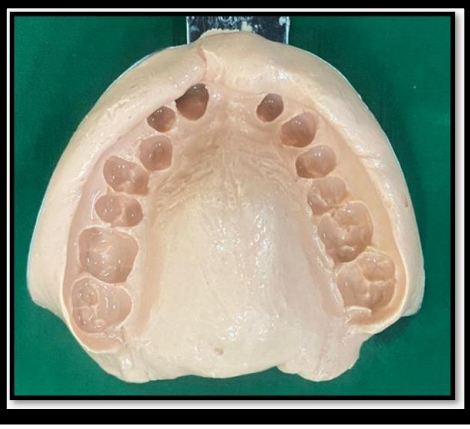

MAXILLARY DIAGNOSTIC IMPRESSION



MANDIBULAR DIAGNOSTIC IMPRESSION



MAXILLARY DIAGNOSTIC CAST



MANDIBULAR DIAGNOSTIC CAST

MOCK PREPARATION







DIAGNOSTIC WAX UP DONE



TOOTH PREPARATION IRT
13,12,21,22,23 DONE



PROVISIONALISATION IRT
13,12,11,21,22,23 DONE





PRE OP



POST OP