Beyond the Fracture: Managing a Traumatized Immature Permanent Incisor with an Unusual Foreign Body.

A Patient aged 12 years reported to the department with the chief complaint of blackish discoloration in the front tooth region, on examination it was a Ellis class 4 fracture irt 21 which was diagnosed as Ellis class 4 fracture with open apex along with foreign body intrusion on radiographic examination.



FRONTAL VIEW



RIGHT LATERALVIEW



LEFT LATERALVIEW



MAXILLA OCCLUSAL VIEW



MANDIBLE OCCLUSAL VIEW



PRE OP FOREIGN MATERIAL IN THE CANAL IRT 21

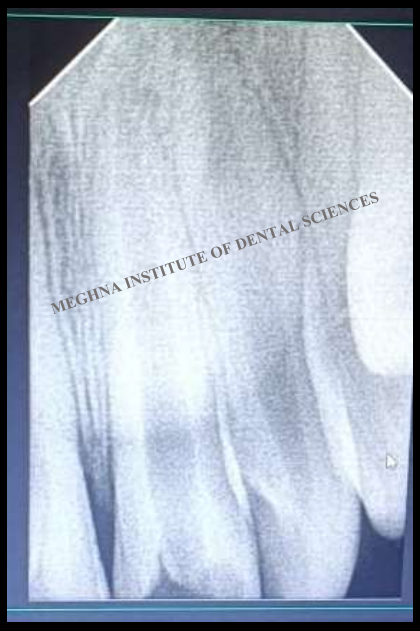

FOREIGN MATERIAL IN THE CANAL IRT 21 RETRIVED



FOREIGN MATERIAL RETRIVED WERE 2 STAPLER PINS

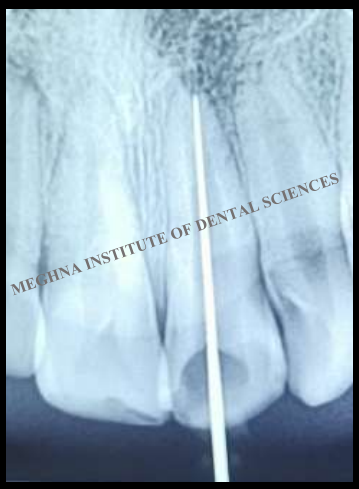

WORKING LENGTH DETERMINED 21 MM

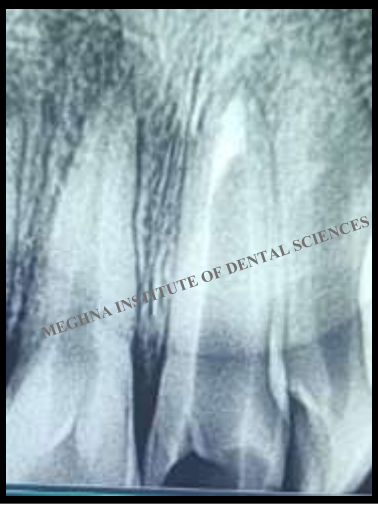

MTA APEXIFICATION DONE IRT 21 (5MM MTA)



GP OBTURATION DONE