Orthodontic Management Of Impacted Canine

A 26 years old adult female patient with Angles class I malocclusion came to the department with the chief complaint of facial asymmetry and irregularly placed upper & lower front teeth, with no relevant medical history. Treatment was planned to correct crossbite, alignment and facial asymmetry.



Pre treatment frontal photograph



Pre treatment smiling photograph



Pre treatment profile photograph



Pre treatment intraoral frontal photograph



Pre treatment intraoral right buccal photograph



Pre treatment intraoral left buccal photograph



Occlusal photograph with Quadhelix



Present stage intraoral frontal photograph



Present stage intraoral buccal left photograph

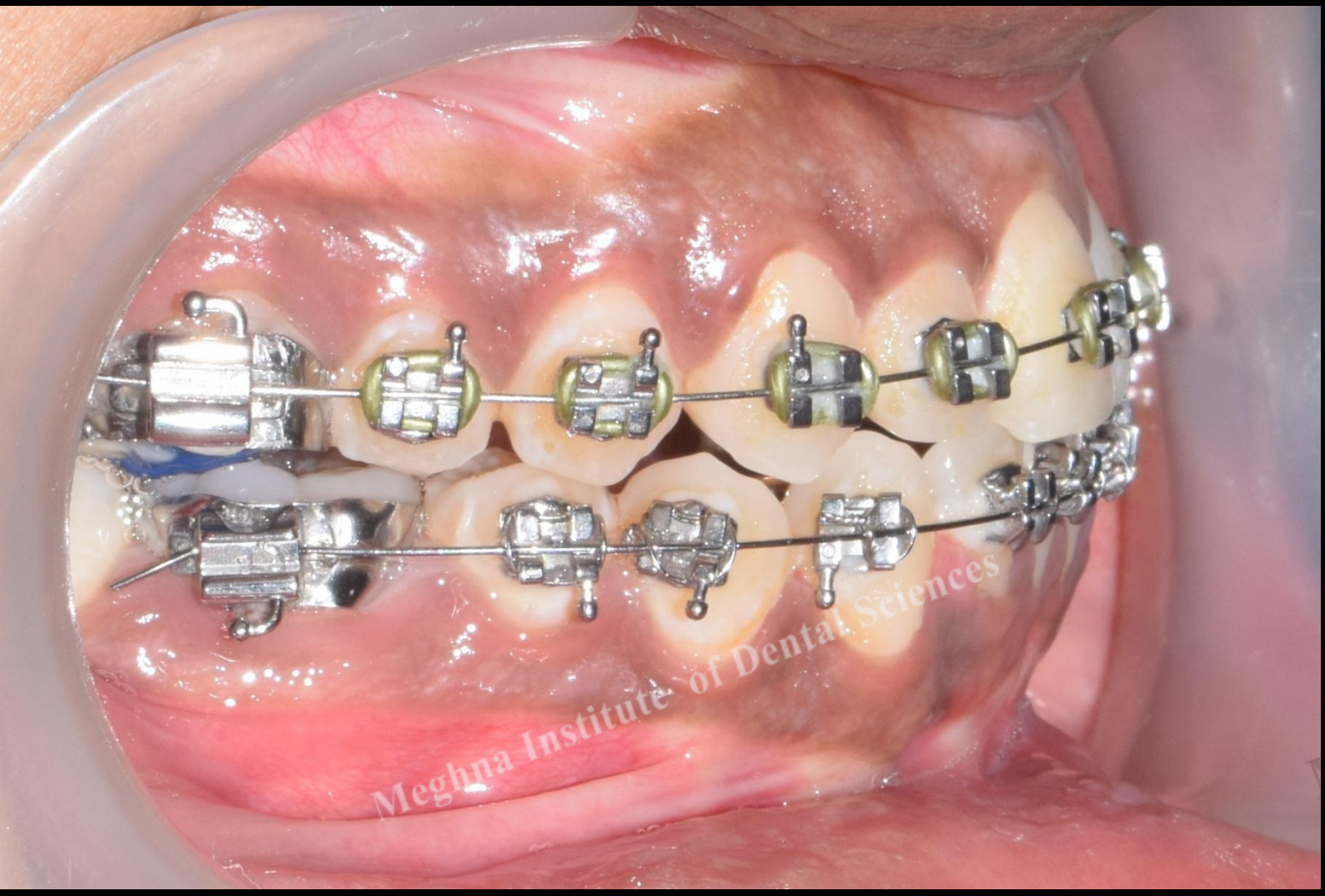

Present stage intraoral buccal right photograph

Present stage intraoral maxillary occlusal photograph



Present stage intraoral mandibular occlusal view photograp

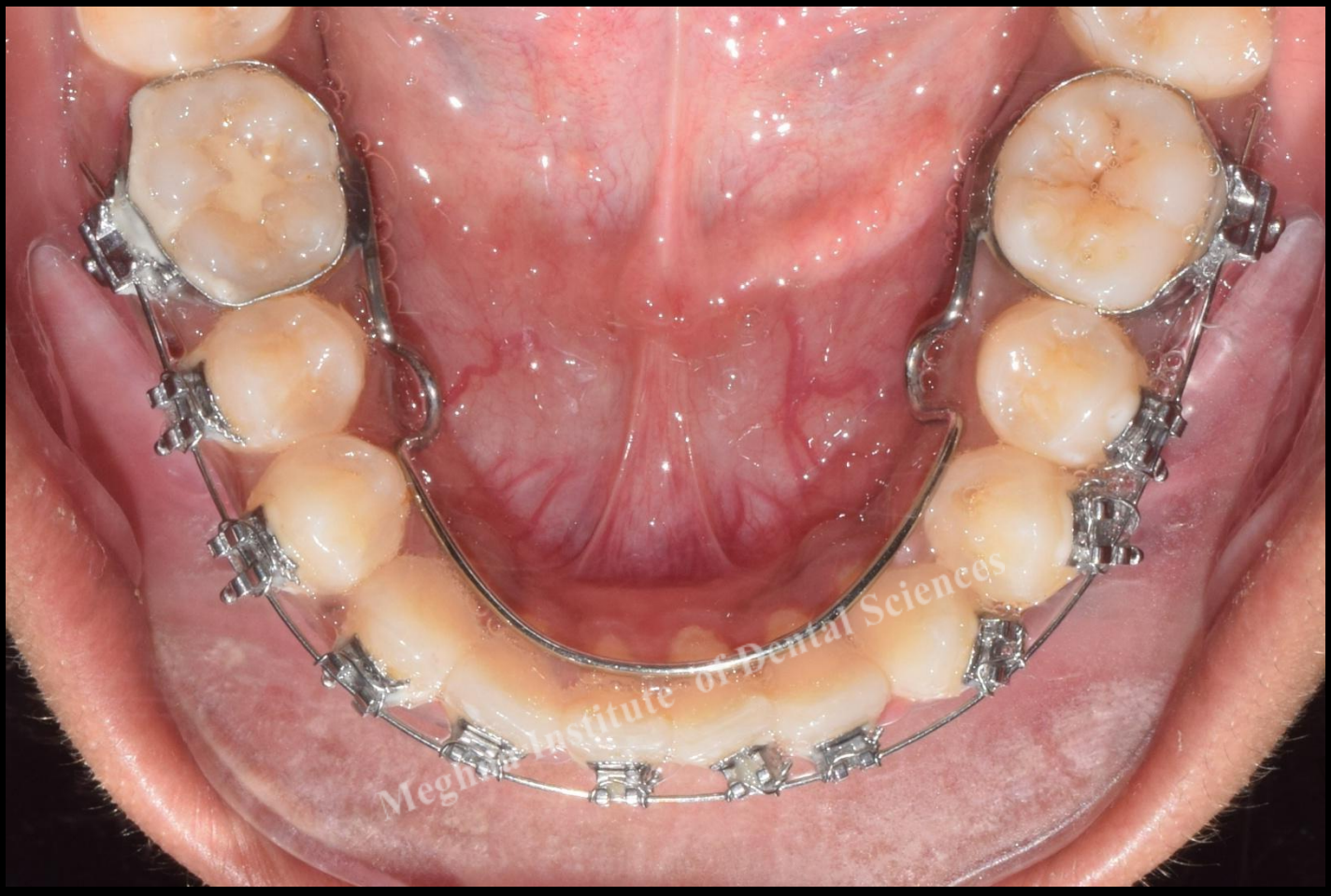

PRETREATMENT



PRESENT STAGE



PRETREATMENT



PRESENT STAGE

