A case of Bilateral Canine Impaction

A 42 year old female patient reported to the department of ORAL AND MAXILLOFACIAL SURGERY, with missing teeth in upper front teeth region.

Bilateral surgical extraction was done.

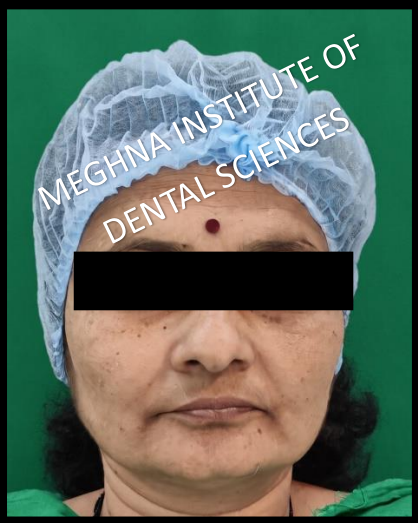

Front profile

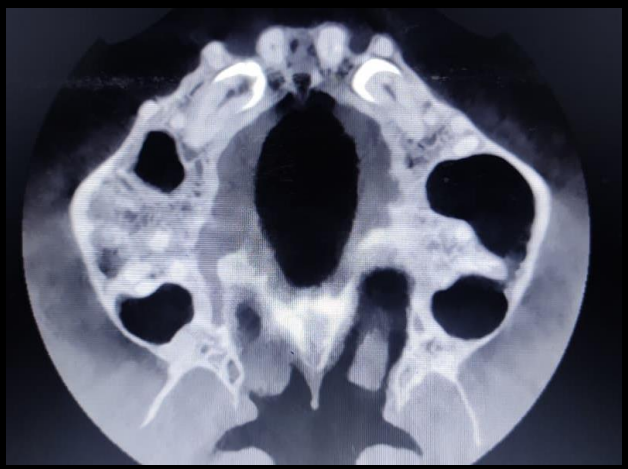

CBCT Evaluation



After administering Local anaesthesia Crevicular Incision is given

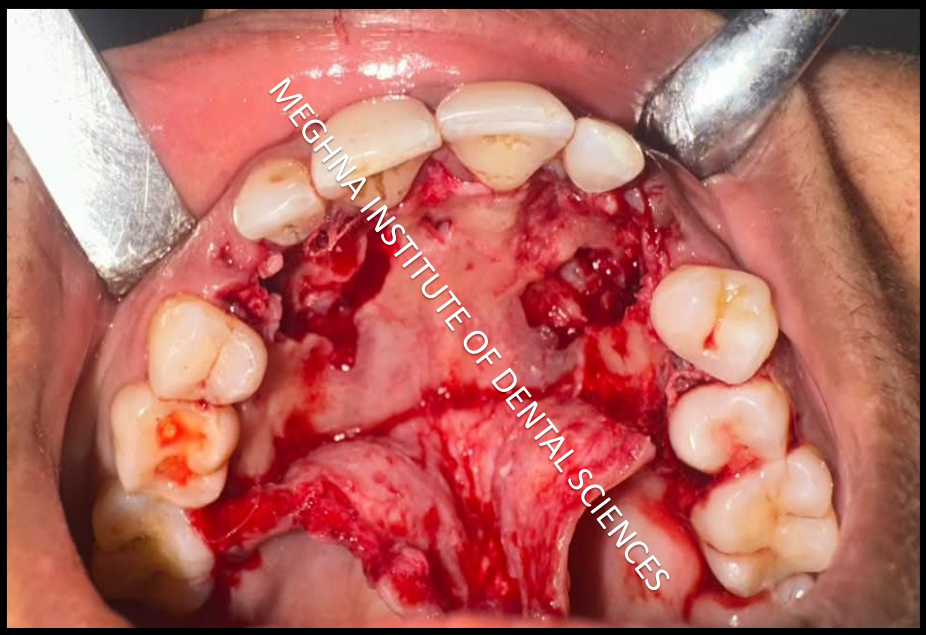

Exposure of impacted Canines



Extracted 13,23



Closure was done with Mersilk