Dens Invaginatus: From Developmental Anomaly to Diagnostic Dilemma

A 24 year old female patient named, Rajitha, reported to the Department of Oral Medicine & Radiology, with a chief complaint of pain in the upper front tooth region since 3 days.On examination, deep palatal groove was seen on 12 & 22,which were tender when percussed.

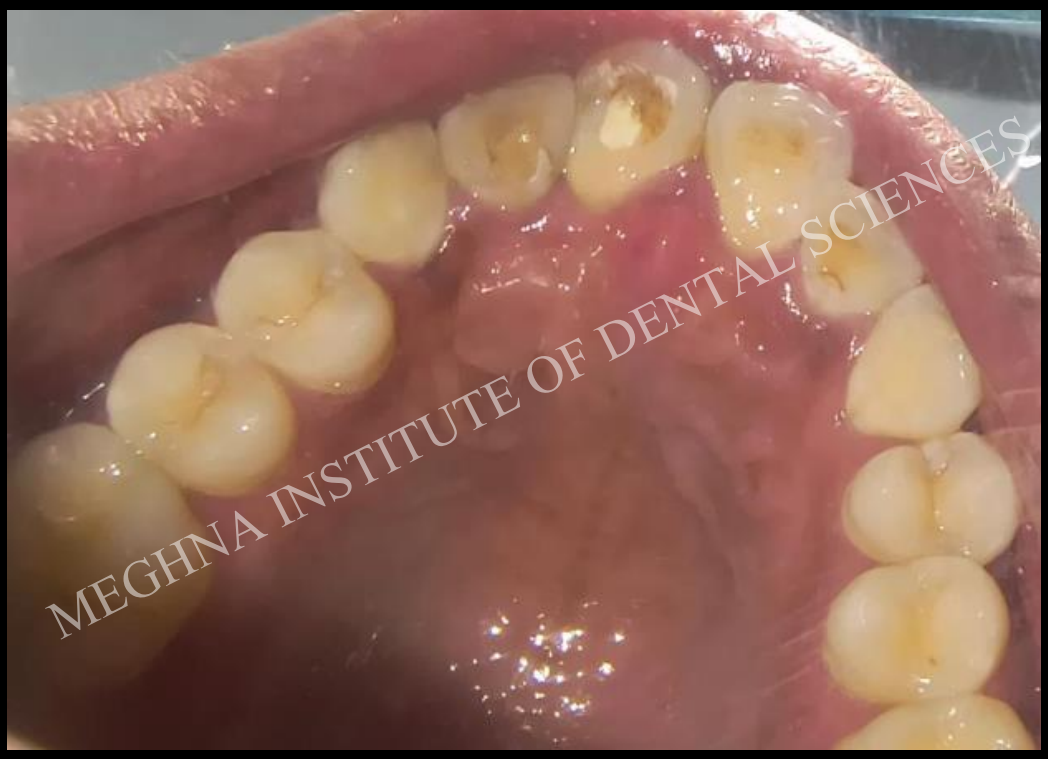

DEEP LINGUAL GRROVE CAN BE APPRECIATED ON 12

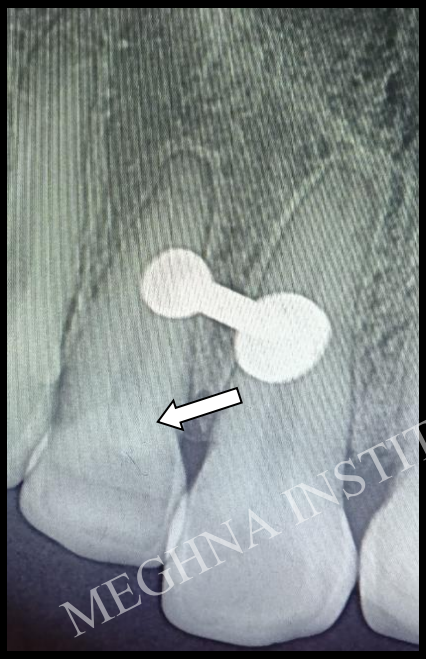

FAINT RADIOLUCENT LINE IRT 12



A CLEAR RADIO-OPAQUE RING IS SEEN IRT 22

MEGHNA INSTITUTE OF DENTAL SCIENCES

On Radiographic Assessment, a subtle, radiolucent line/halo is noted within the coronal portion of the tooth in 12, whereas a distinct ring-shaped radiolucent area surrounded by a relatively radiopaque outline is observed within the coronal aspect of 22 with periapical radiolucency. Provisional Diagnosis was given as Dens Invaginatus leading to Periapical abscess irt 22