“Uncovering The Enigma: Management Of A C-Shaped Root -Canal Configuration.”

- "A 21-year-old female patient reported to the Department of Conservative Dentistry and Endodontics with a chief complaint of severe and continuous pain in the lower left back tooth region for the past 3 days, increasing especially at night and when having hot or cold food. “
- **Clinical examination** revealed deep dental caries irt 37, with severe tenderness on percussion.
- **Pulp vitality testing** revealed a delayed response irt 37.
- **Radiographic examination** revealed deep disto-occlusal radiolucency approaching the pulp chamber with roots appearing distinct and separated radiographically, and with no obvious signs of classic root fusion irt 37.
- **Diagnosis** : Chronic irreversible pulpitis irt 37
- **Treatment plan** : Advised Root canal treatment irt 37

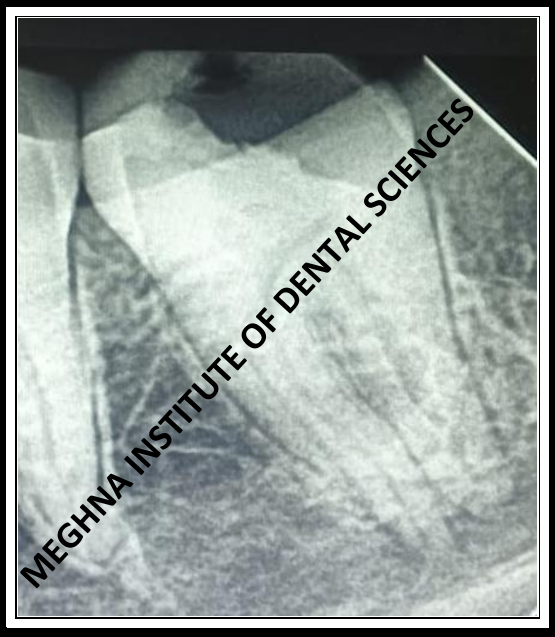

PRE-OPERATIVE irt 37

- **ORIFICE MAPPING AND ANATOMY:**

  - Following conventional access cavity preparation under isolation , examination of the pulp chamber floor revealed a semicolon-shaped orifice configuration irt 37.
  - The internal anatomy comprises a separate, isolated distal orifice separated by a thin dentinal bridge from the mesial aspect, which exhibits two distinct orifices.
  - This configuration confirms a **Melton's Class II (Semicolon type) C-shaped canal anatomy** , independent of the multi-rooted radiographic appearance.

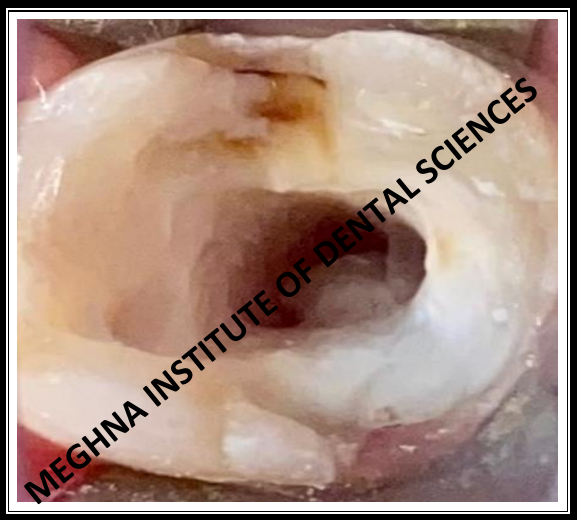

- **<u>WORKING LENGTH DETERMINATION</u>**: Canals were negotiated using #10k file. Mesiolingual(ML): 19mm , Mesiobuccal (MB):19mm, Distal (D): 20mm.



WORKING LENGTH irt 37

- **<u>BIOMECHANICAL PREPERATION:</u>** The canals were shaped using Neoendo file system up to a size of #25/0.6 taper.
- Copious irrigation with 3% Sodium hypochlorite (NaOCl) and 17% EDTA was performed alternately to clean the interconnected semicolon fin area.
- Master Gutta -percha cones were selected and confirmed radiographically.

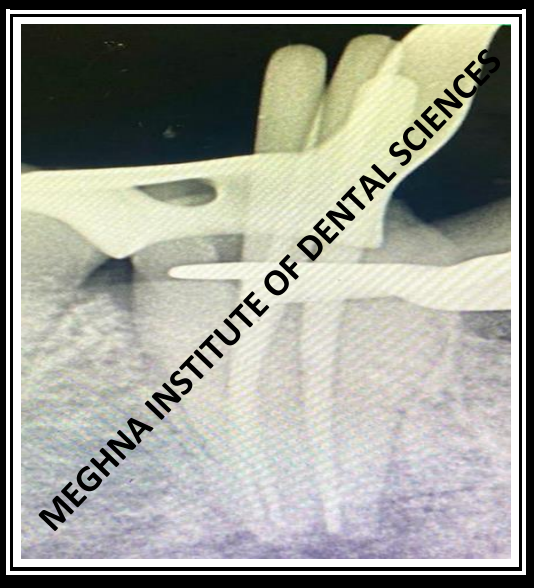

MASTER CONE irt 37

- **<u>OBTURATION AND FINAL RESTORATION:</u>**
- Canals were dried thoroughly with paper points.
- AH Plus sealer was applied along with Gutta -percha cones to achieve a three-dimensional obturation using warm vertical compaction technique .
- This was followed by the placement of a permanent composite core build- up irt 37.



POST-OPERATIVE irt 37