Full Mouth Rehabilitation With Occlusal Reorganization In A Partially Edentulous patient

A 46-year-old female patient reported to the DEPARTMENT OF ORAL AND MAXILLA FACIAL PROSTHODONTICS AND IMPLANTOLOGY with a chief complaint of missing lower posterior teeth and wear off of upper posterior teeth

On clinical examination patient have deep bite

full mouth rehabilitation with correction of occlusal plane and cast partial denture with precision attachment



pre op



Intra oral photographs



opg



Tooth preparations



Face bow transfer



Wax pattern fabrication



Altered cast technique



Permanent cementation and insertion

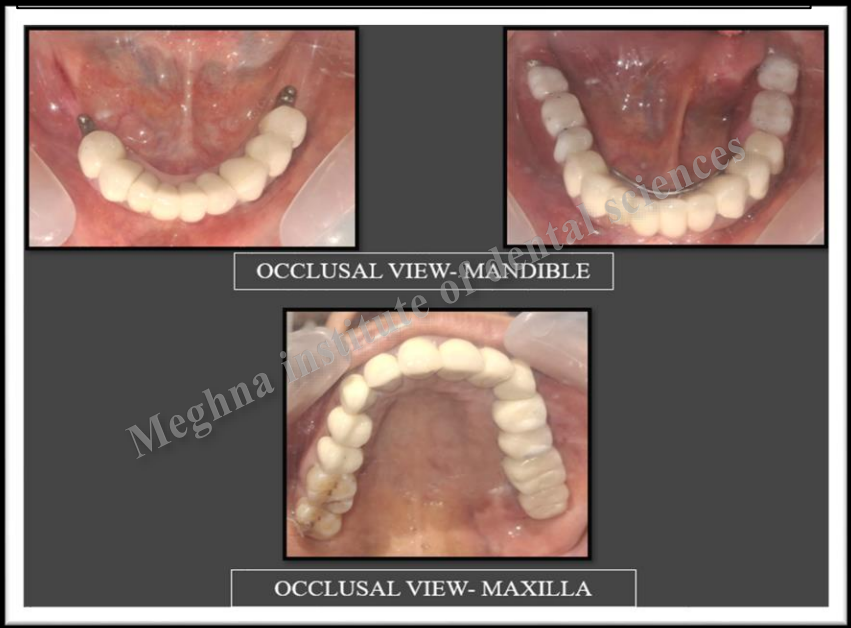

Permanent cementation and insertion



Post op