SOCKET SHIELD WITH IMMEDIATE IMPLANT PLACEMENT IRT 12

A 29-year-old male, Srikanth, reported with a history of trauma in the maxillary anterior region 6 months ago. Clinical examination revealed missing 11, 21, 22 and proclined 12, which was tender on percussion.

Intraoperatively: Internal bevel incision was given in the edentulous region and a full-thickness mucoperiosteal flap was elevated irt 12-23, atraumatic extraction with socket shield preparation was performed by sectioning the root and retaining the buccal root fragment irt 12. The shield was reduced to approximately 1 mm below the crestal bone, carefully debrided and irrigated while maintaining its integrity. The implant osteotomy was subsequently prepared palatal to the retained shield, followed by placement of a **3.3 × 10 mm implant**.



PRE-OPERATIVE IMAGE



PRE-OPERATIVE OPG

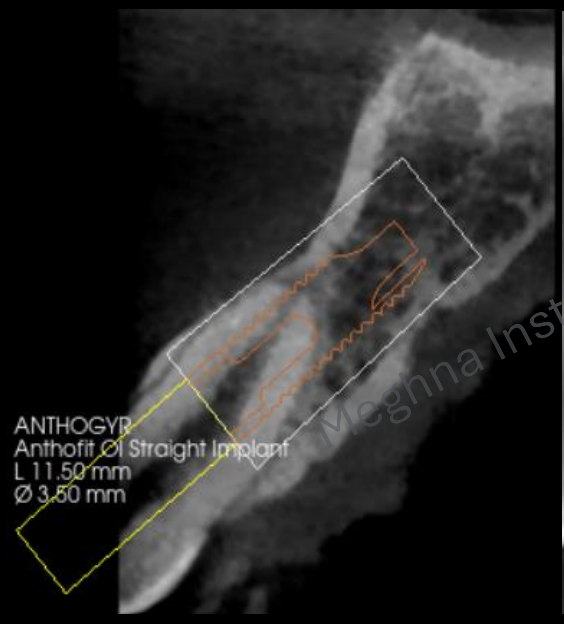

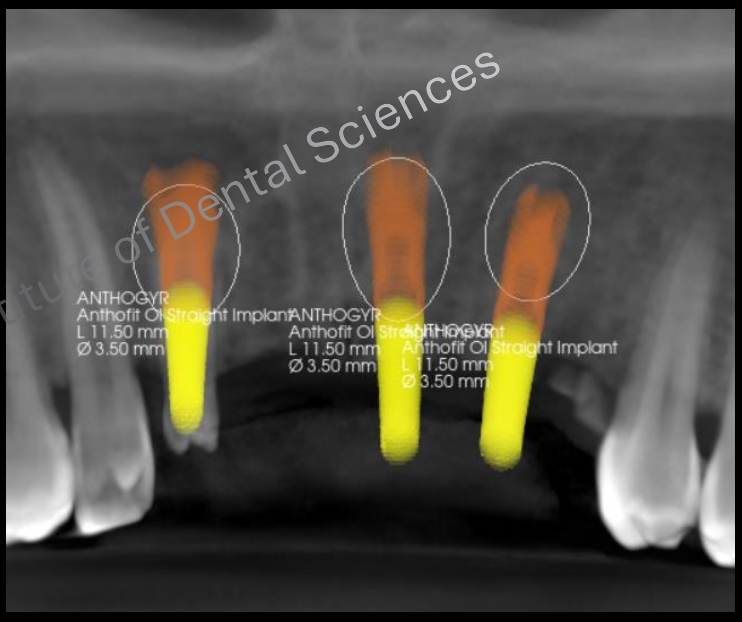

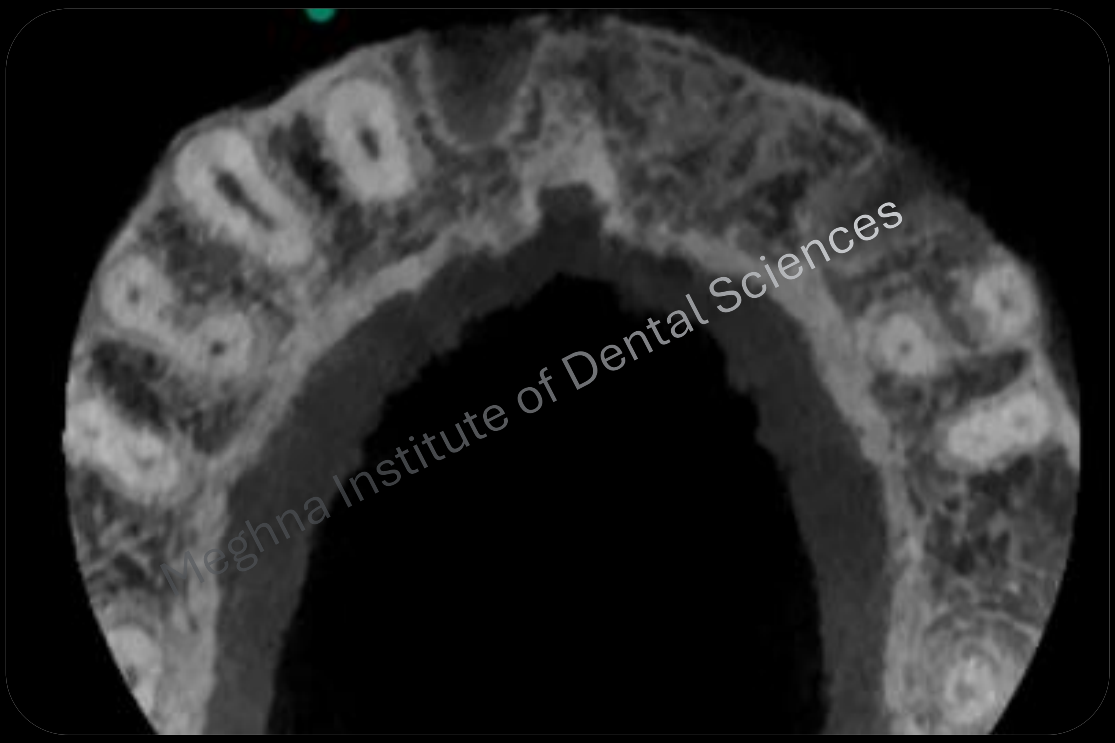

DEFICIENT BUCCAL BONE AVAILABLE FOR IMPLANT PLACEMENT IRT 12



DIAGNOSTIC WAX UP FOR PLANNING OF IMPLANT PROSTHESIS


Meghna Institute of Dental Sciences

FLAP ELEVATION AND DECORONATION DONE IRT 12


Meghna Institute of Dental Sciences

EXTRACTED CROWN PORTION &
PALATAL ROOT FRAGMENT



Socket Shield irt 12

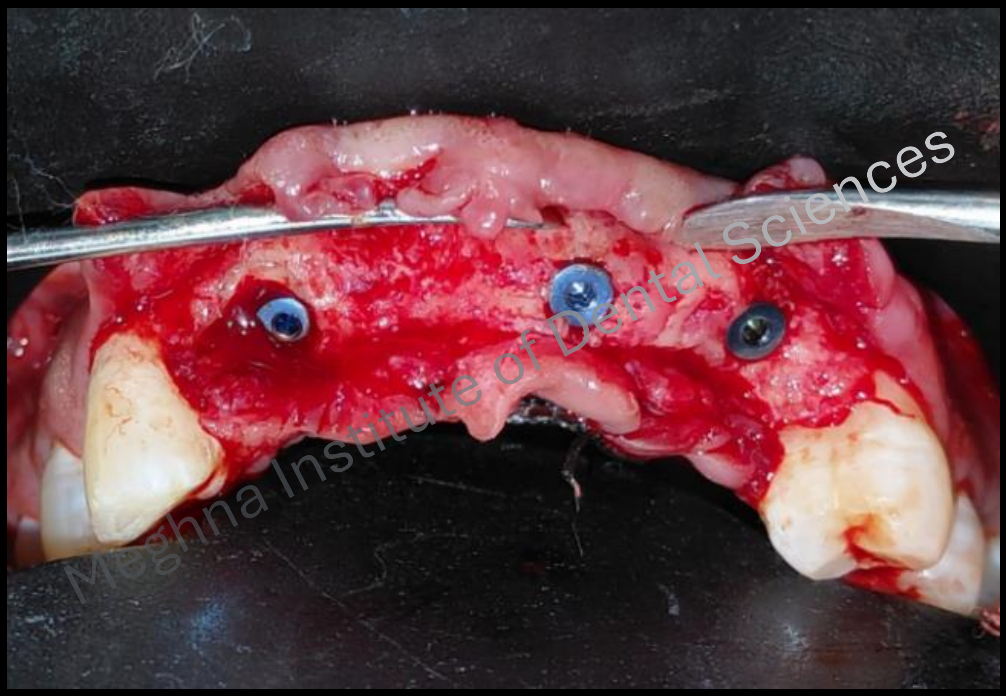

Immediate Implant Placed irt 12.
Delayed Implant Placement irt 21,23.


Meghna Institute of Dental Sciences

Interrupted Sutures Placed

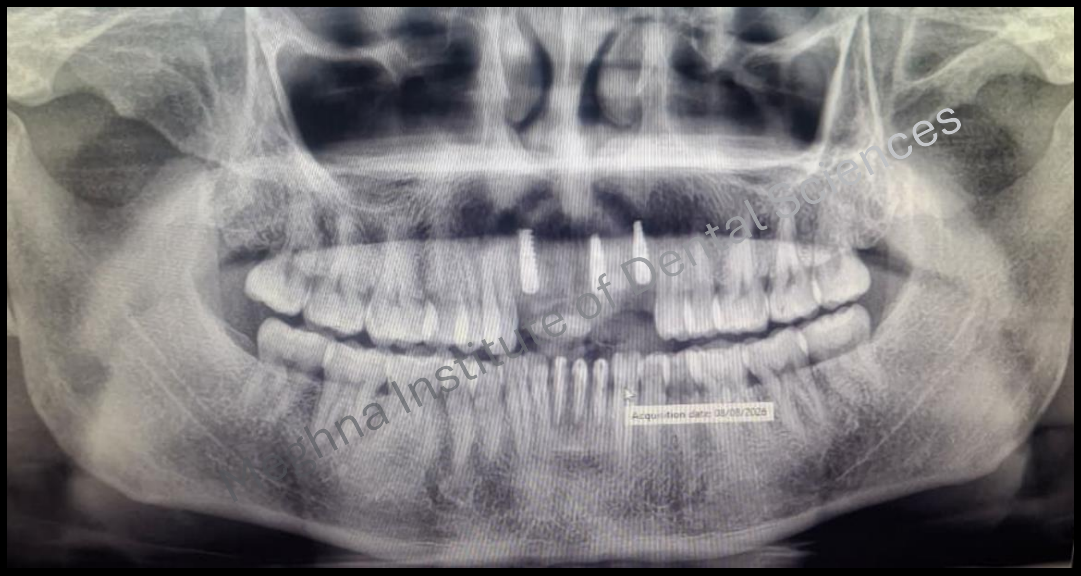
Meghna Institute of Dental Sciences

POST-OPERATIVE OPG AFTER PLACEMENT OF IMPLANTS