An Unusual Third Root in a Primary Molar: A Case of Radix Entomolaris

A Patient aged 8 years reported to the department with the chief complaint of pain in the lower left back tooth region, on examination it was a deep dental caries with radix entomolaris irt 75 which was diagnosed as chronic irreversible pulpitis with radix entomolaris irt 75. Pulpectomy was done in irt 75 followed by which SSC placed irt 75.



FRONTAL VIEW



RIGHT LATERALVIEW



LEFT LATERALVIEW



MAXILLA OCCLUSAL VIEW



MANDIBLE OCCLUSAL VIEW



PRE OP RVG IRT 75 SEEN WITH RADIX ENTOMOLARIS

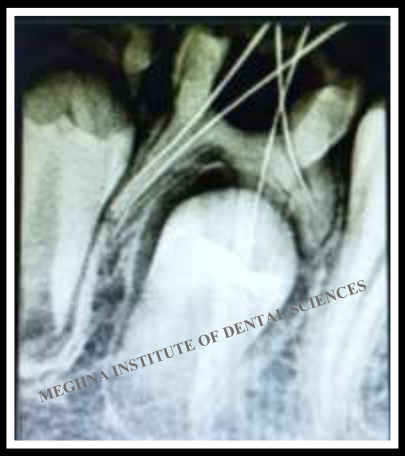

WORKING LENGTH DETERMINED



POST OP RVG IRT 75 OBTURATION DONE



MANDIBLE OCCLUSAL VIEW



LEFT LATERALVIEW



POST OP RVG IRT 75 AFTER SSC PLACED