Orthodontic Management Of Impacted Canine

A 20 years old adult female patient with Angles class I malocclusion came to the department with the chief complaint of irregularly placed upper & lower front teeth, with no relevant medical history. Treatment was planned as extraction of all first premolars to relieve crowding & surgical exposure of canine followed by alignment and space closure .



Pre treatment frontal photograph



Pre treatment smiling photograph



Pre treatment profile photograph



Pre treatment intraoral frontal photograph



Pre treatment intraoral right buccal photograph



Pre treatment intraoral left buccal photograph



Post Surgical exposure of canine intraoral frontal view photograph



Post-surgical exposure of canine left
buccal view intraoral photograph



Canine retraction intraoral Frontal photogr

h

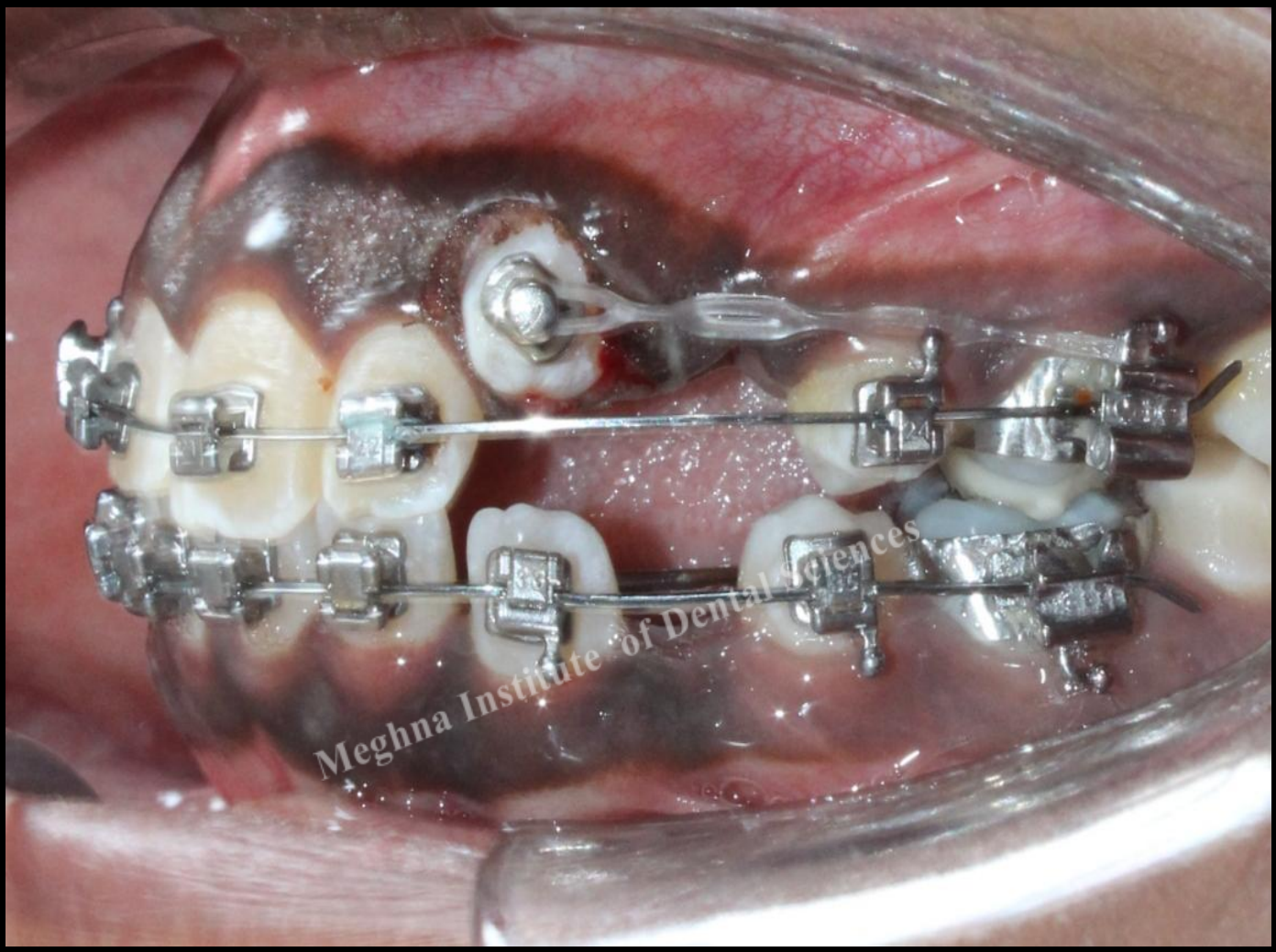

Canine retraction left intraoral buccal view photograph

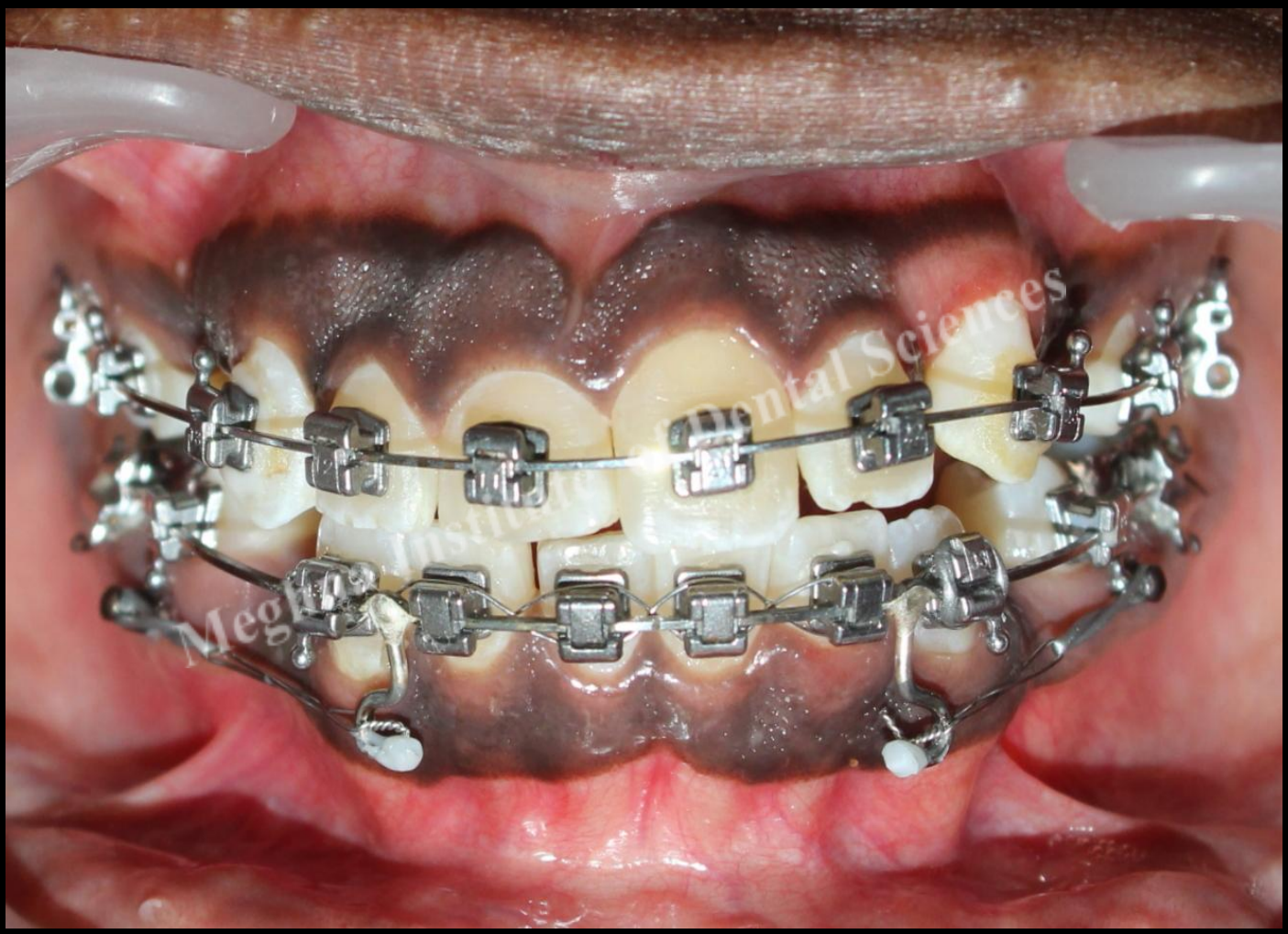

Present stage intraoral frontal view photograph

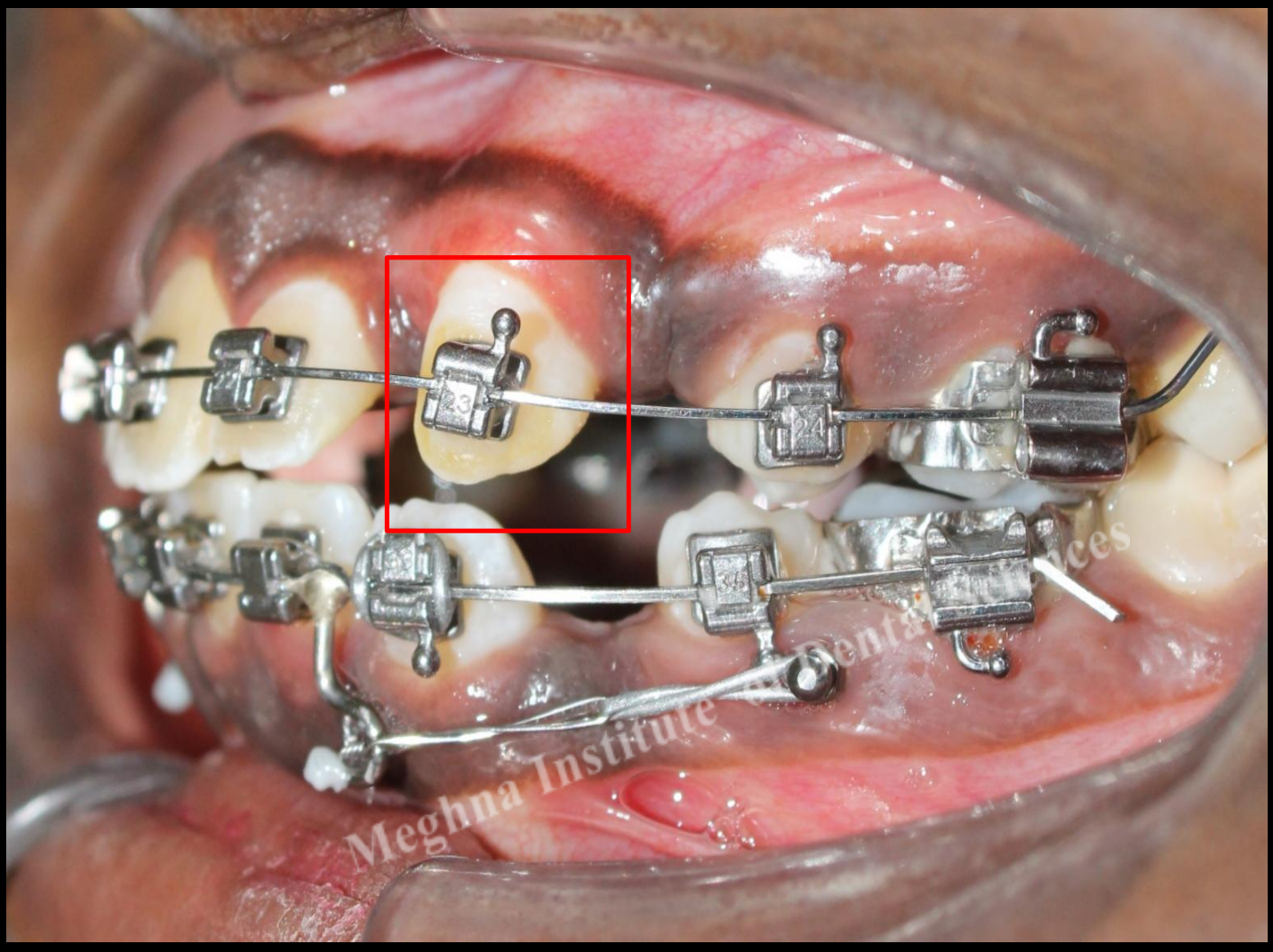

Present stage left intraoral buccal view photograph

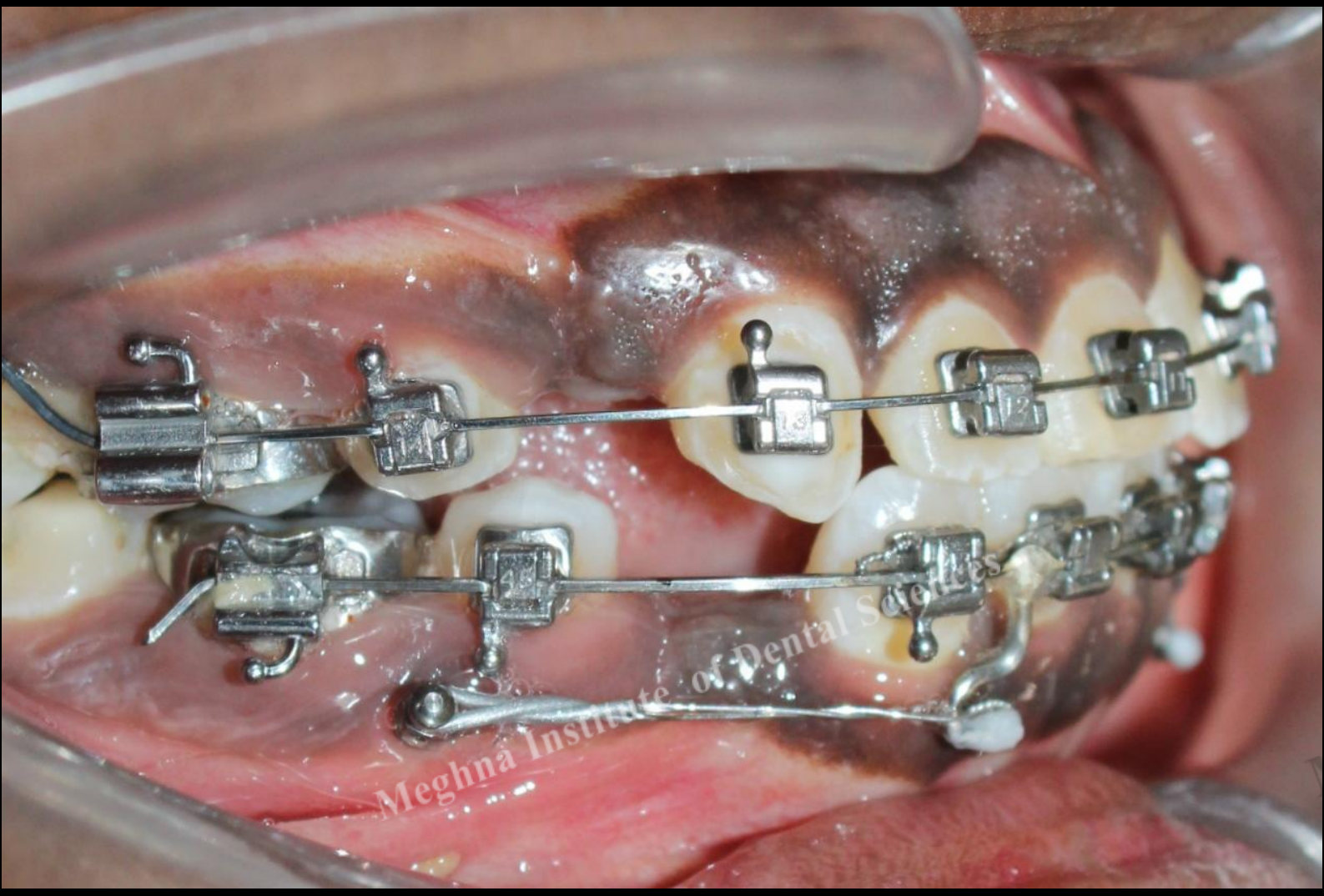

Present stage intraoral right buccal view photograph

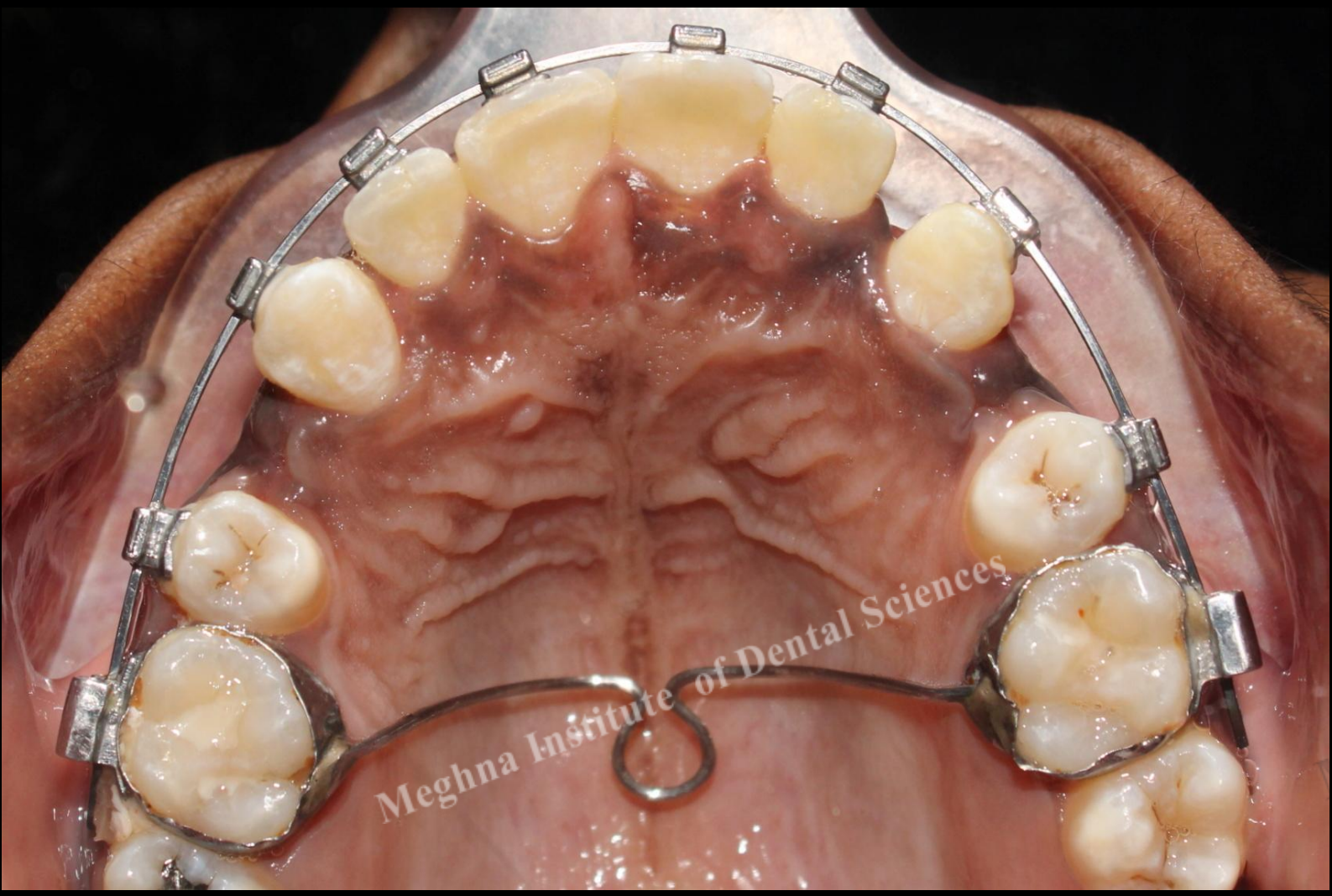

Present stage intraoral occlusal photograph



Present stage intraoral occlusal view photograph



PRETREATMENT



PRESENT STAGE



Pre treatment introral frontal photograph



Present stage intraoral frontal photograph