A case of Ludwing’s angina

A 42 year old female patient reported to the department of ORAL AND MAXILLOFACIAL SURGERY, with painfull swelling in relation to left cheek region, which gradually reached current size.

Surgical incision was given and abscess was drained.



Front profile



LOCAL ANESTHESIA

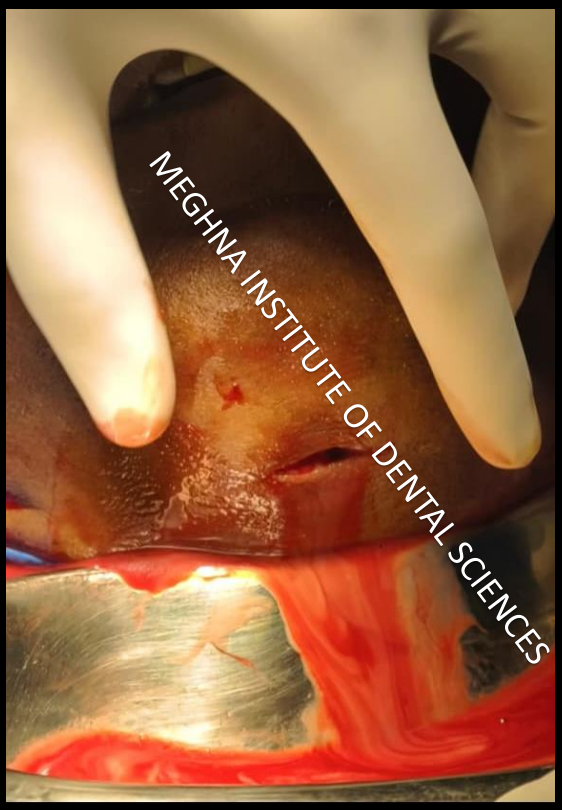

INCISION AND ABSCESS DRAINAGE



DRAIN WAS PLACED FOLLOWED BY ANTIBIOTIC THERAPY