Management Of Flared Root Canals in Fractured Teeth Using An“Anatomic Post”

- "A 36-year-old female patient reported to the Department of Conservative Dentistry and Endodontics with a chief complaint of broken teeth in the upper front tooth region for the past 2 years. “
- Clinical examination revealed a fractured tooth with more than half of the tooth structure lost.



PRE-OPERATIVE CLINICAL VIEW irt 21

- Radiographic examination revealed a loss of coronal tooth structure involving enamel, dentin and pulp irt 21

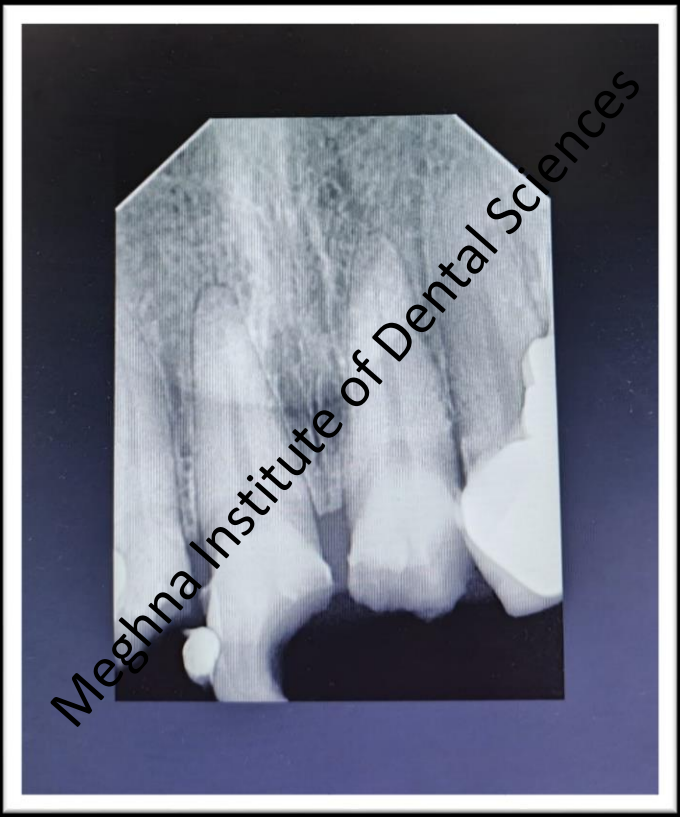

PRE-OPERATIVE RVG IRT 21

- Based on the clinical and radiographic findings, a diagnosis of **"ELLI'S CLASS III FRACTURE" was made** and a treatment plan involving **Root Canal Treatment followed by an Anatomic Post and Core** was formulated



ARMAMENTARIUM

- After access opening , the Working length was determined, followed by BMP using the Step-back technique, and Obturation was performed. Post space preparation was performed using Peesoreamers with apical 4-5 mm of Guttapercha and fiber post try-in was performed.



WORKING LENGTH irt 21



BMP irt 21



OBTURATION irt 21



POST SPACE PREPARATION irt 21

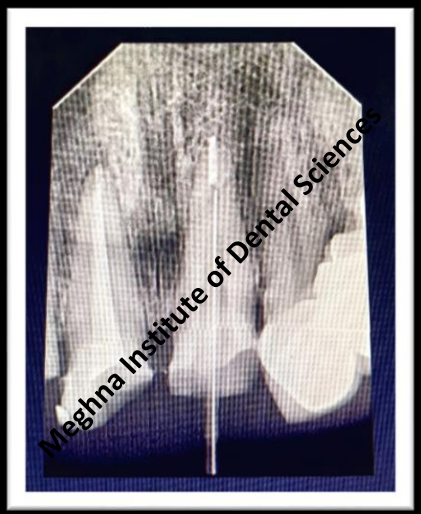

FIBER POST TRY IN irt 21

Initially, a bonding agent was applied to the fiber post and light cured.This was followed by root canal space conditioniing with the application of bonding and light curing irt 21.This was followed by Composite corebuildup done irt 21

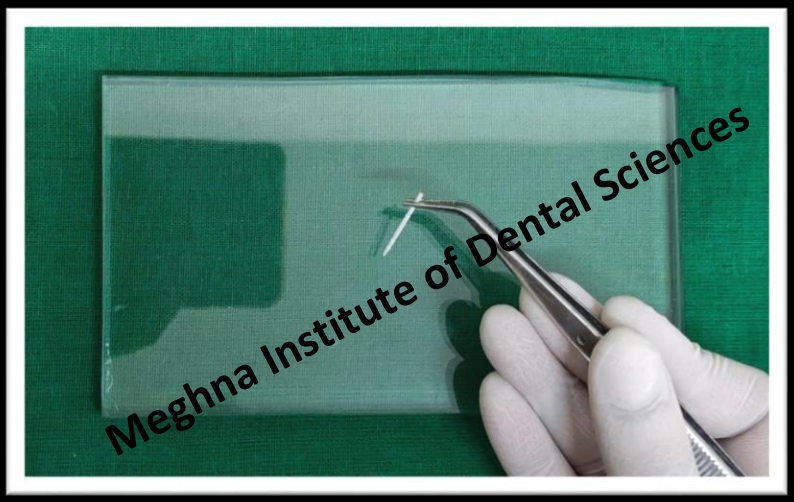





Composite was incrementally applied to the fiber post and adapted to the canal space. After radiographic confirmation of complete adaptation to canal space , the Customized Anatomic Post was cured extraorally and by using luting cement, the post was cemented into the root canal.

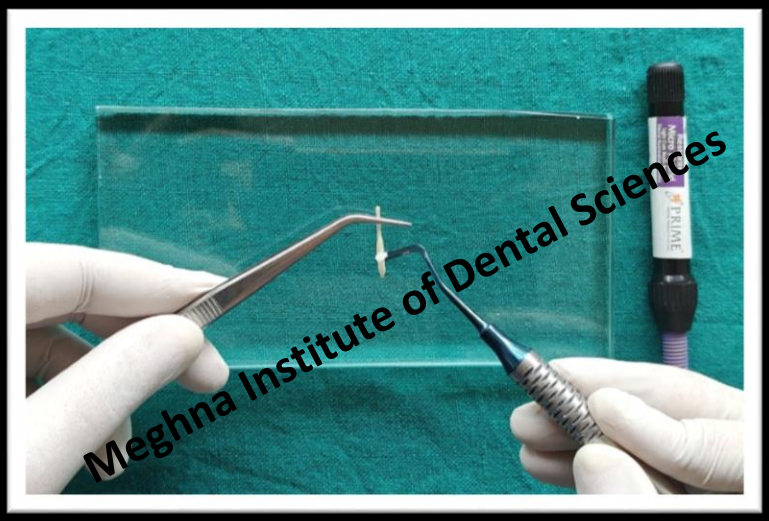

INCREMENTAL APPLICATION OF COMPOSITE

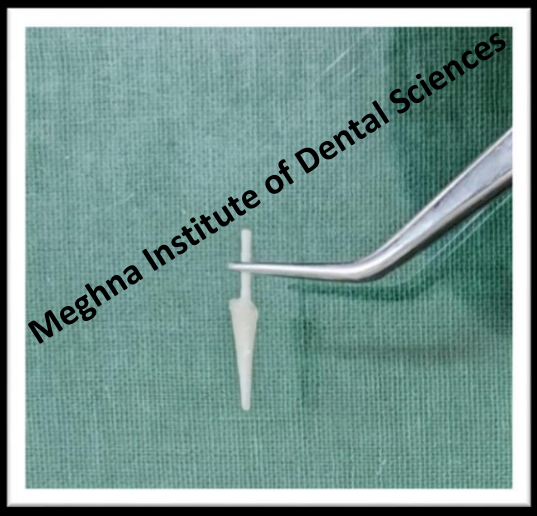

COMPOSITE ANATOMIC POST

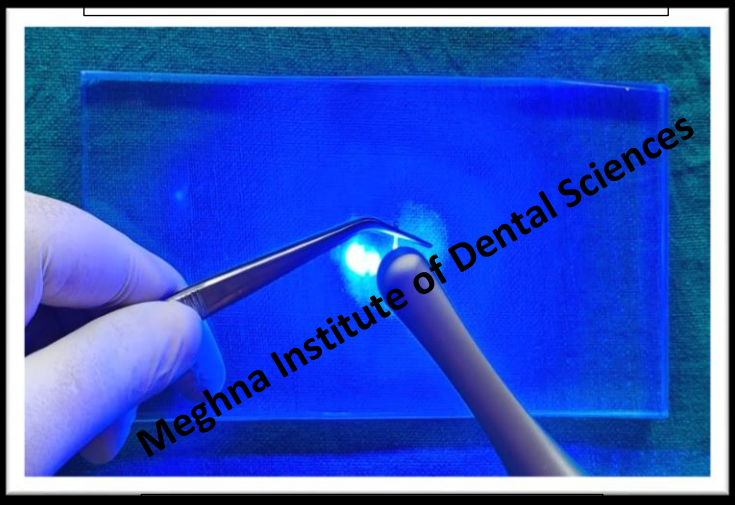

EXTRA ORAL CURING

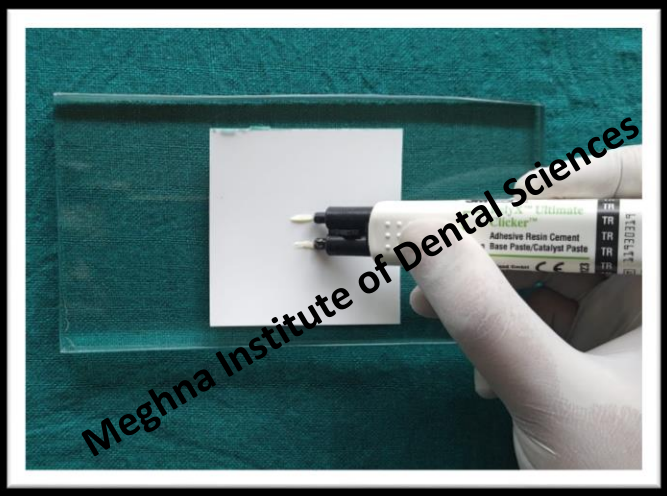

LUTING CEMENT



CEMENTATION



ANATOMIC POST FIT

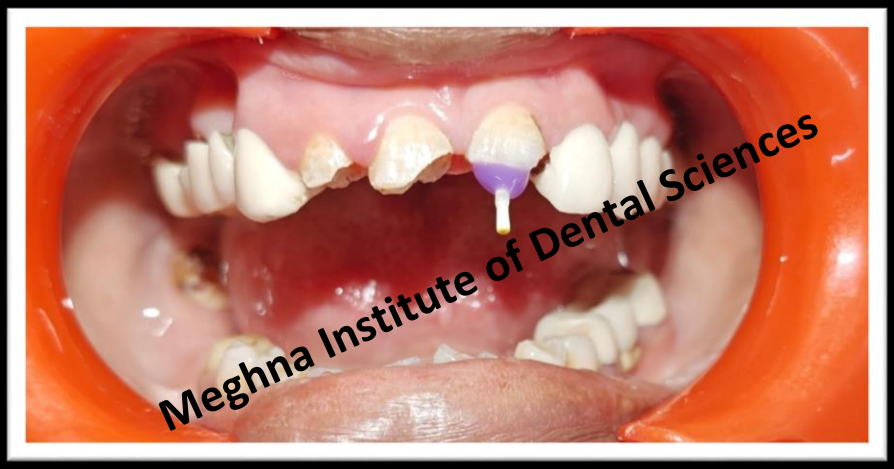

ETCHING irt 21

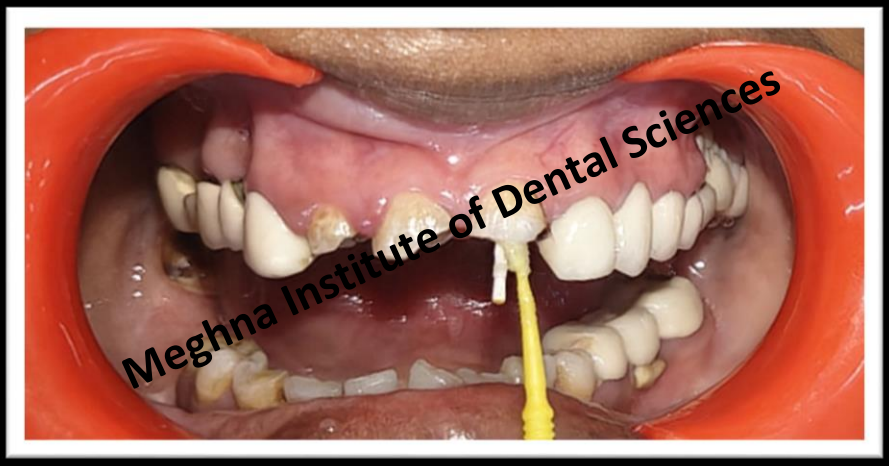

BONDING AGENT APPLICATION irt 21



COMPOSITE CORE BUILD UP irt 21

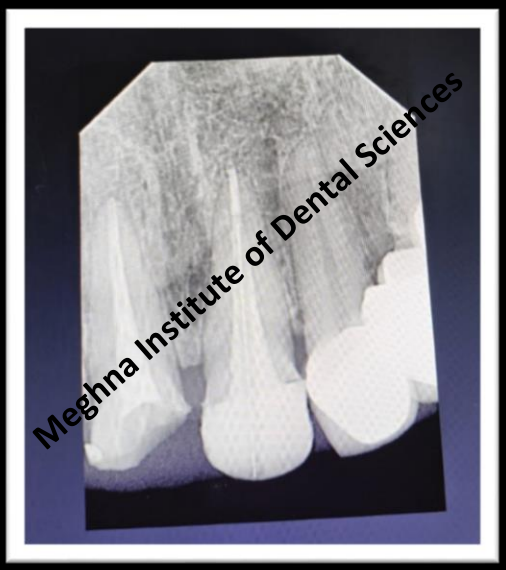

Post-operative radiograph showing complete adaptation of the ANATOMICAL POST with Composite Core buildup irt 21.